

SHOULDER DYSTOCIA

This LOP is developed to guide clinical practice at the Royal Hospital for Women. Individual patient circumstances may mean that practice diverges from this LOP.

1. AIM

- Perform appropriate manoeuvres to free the impacted fetal shoulder in a sequential coordinated process

2. PATIENT

- Woman who is unable to deliver the anterior fetal shoulder following the normal amount of axial traction from the birth accoucheur

3. STAFF

- Medical and midwifery staff

4. EQUIPMENT

- Doppler
- Cardiotocograph

5. CLINICAL PRACTICE

- Summon immediate help once shoulder dystocia is suspected or confirmed
- Discourage maternal pushing
- Call Obstetric PACE tier 2, if immediate help is not adequate in skill or number, to facilitate rapid attendance of skilled personnel
- Request immediate paediatric attendance (if not already present)
- Note the time
- Ensure a staff member adopts the role of 'scribe'
- Attempt to free the impacted fetal shoulder by performing the following external and internal manoeuvres for 30 seconds each in turn: (refer to Appendix 1)
 - McRoberts manoeuvre
 - Lay the woman flat and remove her legs from stirrups if she is in lithotomy
 - Flex the woman's hips, positioning her thighs up onto her abdomen
 - Assist the woman to maintain this position
 - Suprapubic pressure (Rubin I manoeuvre)
 - Reduce the fetal bisacromial diameter by asking an assistant to stand on the side of fetal back and apply pressure just above the maternal symphysis in a downward and lateral direction to push the posterior aspect of the anterior shoulder towards the fetal chest.
 - Be aware that there is no clear difference in efficacy between continuous pressure and rocking 'CPR like' movement.
- Escalate to obstetric consultant attendance (if not already present)
- Perform an episiotomy, if possible, where internal manoeuvres are required
- Use the following described methods for internal rotation to disimpact the anterior shoulder.
 - Rubin II manoeuvre
 - Insert the fingers of one hand vaginally on the side of the fetal back
 - Place fingers on the back of the anterior shoulder at the scapula
 - Push the anterior shoulder towards the fetal chest to disimpact the shoulder from under the symphysis
 - Woods Screw manoeuvre
 - Leave the fingers on the scapula of the anterior shoulder
 - Place fingers on the anterior aspect of the posterior shoulder
 - Attempt to rotate the shoulders to aid delivery

CLINICAL POLICIES, PROCEDURES & GUIDELINES

Approved by Quality & Patient Care Committee
7 July 2016

SHOULDER DYSTOCIA cont'd

Reverse Woods Screw

- Slide the hand that is on the scapula of the anterior shoulder down to scapula of the posterior shoulder
- Attempt to rotate the shoulders in the opposite direction to aid delivery

Removal of the posterior arm

- Slide your other hand from the anterior aspect of the posterior shoulder to the anterior aspect of the anterior shoulder
- Remove second hand
- Re-insert a hand into the vagina posteriorly, flex the posterior arm at the elbow and sweep forearm across fetal chest until the hand is reachable
- Deliver the posterior arm
- Roll the woman over to an "all fours" position if possible:
 - Attempt to deliver the posterior shoulder using axial flexion
 - Consider this manoeuvre after McRoberts and before internal manoeuvres if the woman is mobile
 - Note that all internal manoeuvres can be attempted in an "all fours" position
- Repeat all manoeuvres again
- Attempt auscultation of fetal heart if repeat manoeuvres are unsuccessful
- Escalate if not already done so.
- Consider extreme maneuvers with as much assistance as possible:
 - cleidotomy
 - symphysiotomy
 - Zavanelli manoeuvre
- Document thoroughly in Integrated Clinical Notes the time interval from the birth of the head to birth of the neonate and the steps and manoeuvres used to deliver the neonate
- Complete the RHW Shoulder Dystocia Proforma (Appendix 2) and file in the woman's Integrated Clinical Notes
- Collect cord blood for pH and record the results in the clinical notes
- Debrief with the woman and family
- Facilitate appropriate debrief for staff members where required

6. DOCUMENTATION

- Integrated Clinical Notes (Maternal and Neonatal)
- Shoulder Dystocia Documentation Chart

7. EDUCATIONAL NOTES

- The definition of shoulder dystocia is a vaginal vertex delivery that requires additional obstetric manoeuvres to deliver the fetus after the head has delivered. It is an obstetric emergency
- Shoulder dystocia is suspected after the head emerges and then retracts up against the perineum (turtle sign)
- Diagnosis is made when the shoulders are in the anterior/posterior position and fail to deliver despite routine traction and/or maternal effort
- Reported incidence of shoulder dystocia is approximately 0.7% of vaginal deliveries
- Perinatal morbidity from shoulder dystocia includes hypoxia, brachial plexus injury and fractures
- Perinatal mortality may result from severe shoulder dystocia
- Maternal morbidity includes postpartum haemorrhage (PPH) and perineal trauma
- There are antenatal and intrapartum risk factors associated with shoulder dystocia (see appendix 3), although these have a low positive predictive value.

CLINICAL POLICIES, PROCEDURES & GUIDELINES

Approved by Quality & Patient Care Committee
7 July 2016

SHOULDER DYSTOCIA cont'd

- 48% of births complicated by shoulder dystocia occur with neonates with birth weight <4kg
- Where risk factors for shoulder dystocia have been identified, a well documented plan for birth should be recorded in the clinical notes
- An obstetric registrar and/or obstetric consultant should counsel women with a history of previous shoulder dystocia in the antenatal period of any subsequent pregnancy
- There is no clear requirement to recommend elective caesarean birth routinely to women with a history of shoulder dystocia. However, factors such as the severity of any previous neonatal or maternal injury, predicted fetal size and maternal choice should all be considered and discussed with the woman and her family when making plans for the next delivery
- Excessive force or fundal pressure are unlikely to free the impacted shoulder and may cause fetal or maternal injury
- Routine traction in an axial direction can be used to diagnose shoulder dystocia but any other traction should be avoided. Axial traction is in line with the fetal spine i.e. without lateral deviation.
- Evidence from cadaver studies suggests that lateral and downward traction, and rapidly applied traction, are more likely to cause nerve avulsion and are strongly associated with obstetric brachial plexus injury
- McRoberts manoeuvre straightens the lumbosacral angle, increases the relative anterior/posterior diameter of the pelvis and increases the interspinous diameter. It is effective, with reported success of up to 90%.
- There are no randomized comparative studies available comparing internal rotation with delivery of the posterior arm
- The “all fours” position is a safe, rapid and effective technique for the reduction of shoulder dystocia with the pelvic diameters increasing from the semi-recumbent position. The true obstetrical conjugate increases by as much as 10mm and the sagittal measurement of the pelvic outlet increased up to 20mm
- The use of episiotomy will not aid the disimpaction of the shoulders but may assist with access to facilitate internal manoeuvres
- “Shoulder Dystocia” reminder cards are located in each Delivery Suite room and these may be useful to guide documentation
- Accurate and comprehensive documentation is essential
- Annual simulations and team drills with a manikin is recommended for all midwives and doctors involved in the care of labouring women in order to practice the manoeuvres required to free a shoulder dystocia

8. RELATED POLICIES / PROCEDURES / CLINICAL PRACTICE LOPs

- Second Stage of Labour Care Recognition of Normal Progress and Management of Delay
- Neonatal Resuscitation Guidelines at Delivery
- Postpartum Haemorrhage - Prevention and Management
- Third and Fourth Degree Perineal Tears - Repair and Management
- Obesity and Weight Gain in Pregnancy, Labour and Postpartum
- Pace Management of Deteriorating Adult and Maternity Inpatient (PACE)
- Induction of Labour Policy and Procedure
- Induction of Labour for a Woman with a Postdates Low Risk Pregnancy
- SESLHD Gestational Diabetes Mellitus Management (GDM) Policy
- SESLHD Pre-Gestational Diabetes in Pregnancy Policy – Management of
- First Stage of Labour Care Recognition of Normal Progress and Management of Delay
- Instrumental Vaginal delivery

CLINICAL POLICIES, PROCEDURES & GUIDELINES

Approved by Quality & Patient Care Committee
7 July 2016

SHOULDER DYSTOCIA cont'd

9. RISK RATING

- Medium

10. NATIONAL STANDARD

- CC – Comprehensive Care

11. REFERENCES

- 1 American Academy of Family Physicians, (2000) *Advanced Life Support in obstetrics course syllabus 4th edition*
- 2 RCOG Green Top Guideline No.42 Shoulder Dystocia *2nd edition March 2012*

REVISION & APPROVAL HISTORY

Reviewed and endorsed Maternity Services LOPs group 7/6/16
Approved Quality Council (titled *Shoulder Dystocia Guideline*)
Reviewed November 2006
Approved Quality Council 19/6/06
Endorsed Maternity Services Clinical Committee 11/4/06

FOR REVIEW : JULY 2019

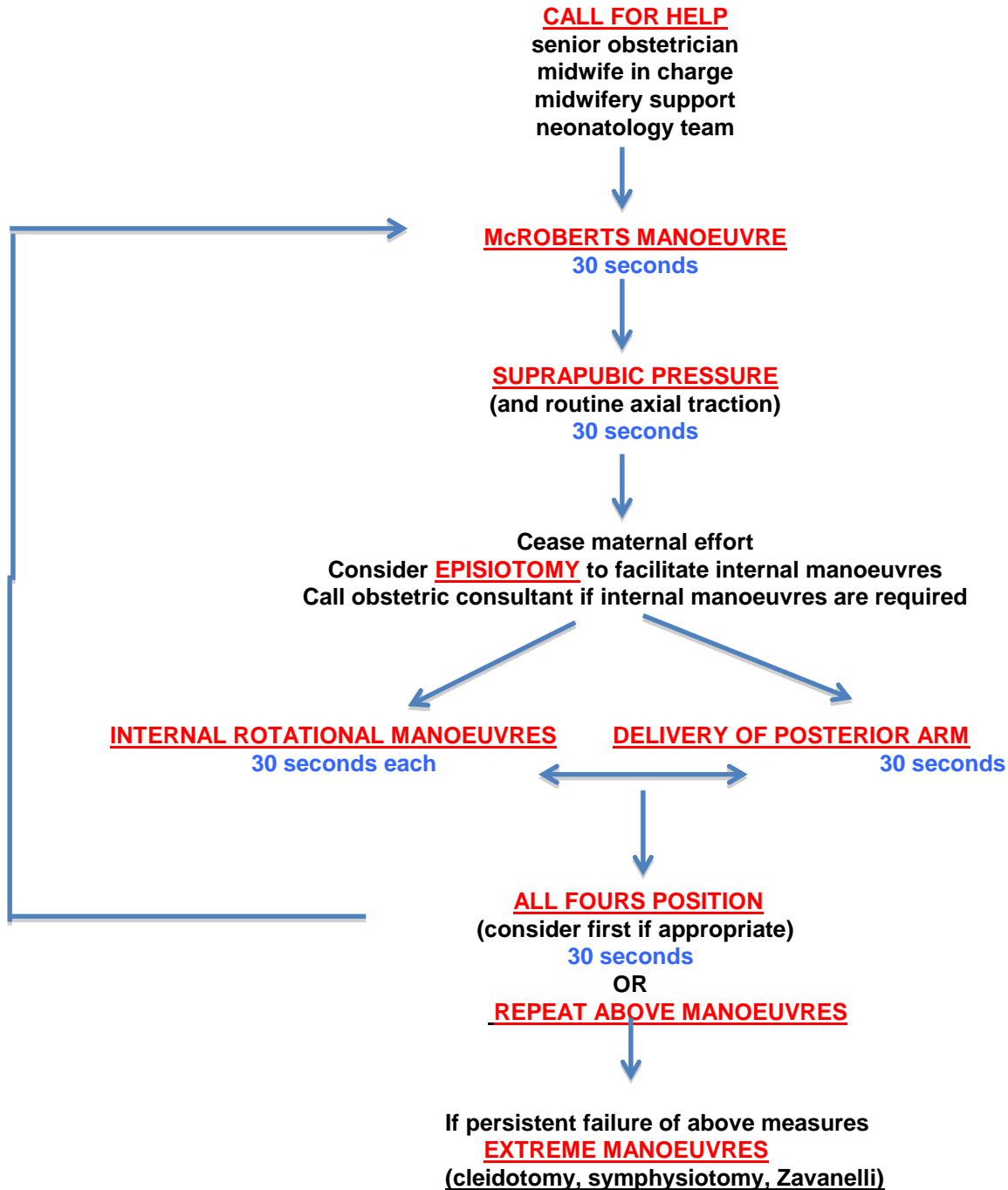
CLINICAL POLICIES, PROCEDURES & GUIDELINES

Approved by Quality & Patient Care Committee
7 July 2016

SHOULDER DYSTOCIA cont'd

APPENDIX 1

MANAGEMENT OF SHOULDER DYSTOCIA ALGORITHM



CLINICAL POLICIES, PROCEDURES & GUIDELINES

Approved by Quality & Patient Care Committee
7 July 2016

SHOULDER DYSTOCIA

**APPENDIX 2
SHOULDER DYSTOCIA DOCUMENTATION**

Shoulder dystocia is defined as “impaction of the anterior shoulder against the maternal symphysis pubis after the fetal head has been birthed.” RCOG (2012). It is diagnosed when additional manoeuvres are required to deliver the fetal shoulders after normal gentle downward traction has failed.

Comprehensive documentation of the event is critical and may include:

H	Called for help at:		Emergency call via switchboard at:	
	Staff present at delivery of head		Additional staff attending for delivery of shoulders:	
	Name:	Designation	Name	Designation
	Manoeuvres used	Clinician's name	Time Frame	Comments
E	Episiotomy			
L	McRoberts position			
P	Suprapubic pressure (Rubin I)			From maternal Right/Left
E	Rubin II			
	Woods Screw			
	Reverse Woods Screw			
R	Removal of the posterior arm			Right/Left arm
R	Roll woman onto all fours			

FURTHER USEFUL INFORMATION

- Describe the traction applied
- Other manoeuvres used
- Time:
 - head delivered
 - body delivered
 - Interval between delivery of head and birth
- Head position at delivery
- Which fetal shoulder was impacted ? left/right,? anterior/posterior
- Position of woman

CLINICAL POLICIES, PROCEDURES & GUIDELINES

Approved by Quality & Patient Care Committee
7 July 2016

SHOULDER DYSTOCIA cont'd

Appendix 3. FACTORS ASSOCIATED WITH INCREASED RISK OF SHOULDER DYSTOCIA

Pre-labour	Intra partum
Previous shoulder dystocia	Prolonged first stage
Macrosomia >4.5kg	Secondary arrest
Diabetes Mellitus (Gestational or Pre-gestational)	Prolonged second stage
Maternal BMI >30	Oxytocin augmentation
Induction of labour	Assisted vaginal delivery