

SAQ 1

A 35 yr old male who presents to your Emergency Department complaining of palpitations, dyspnoea, and light-headedness for the preceding hour. He has no known past medical history.

Vital signs:

BP 115/65

RR 20

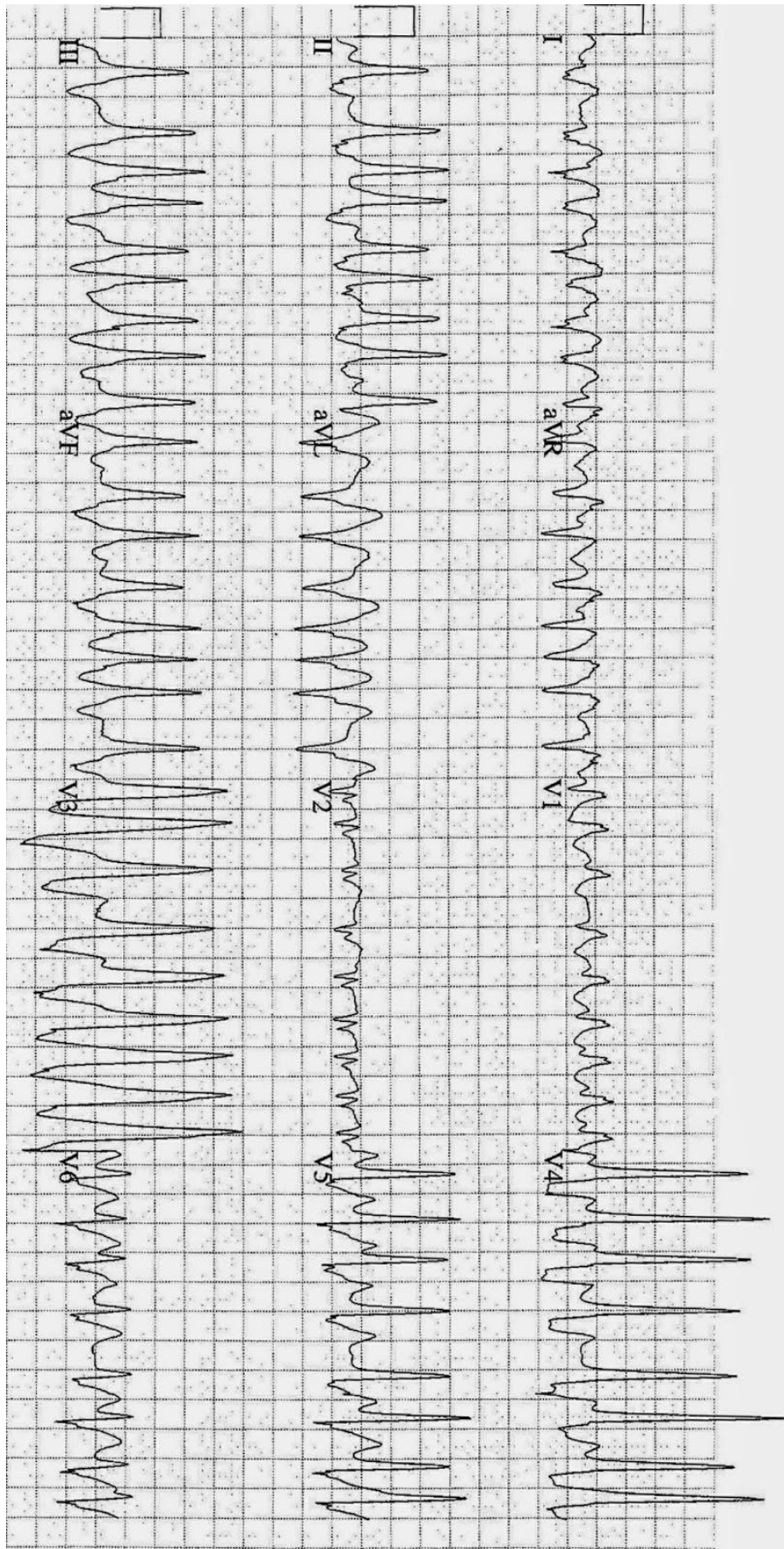
Sats 98% RA

Temp 36.6 °C

a. Describe and his ECG (3 Marks)

b. Interpret his ECG 2 Marks)

c. Outline your management of this patient (5 Marks)

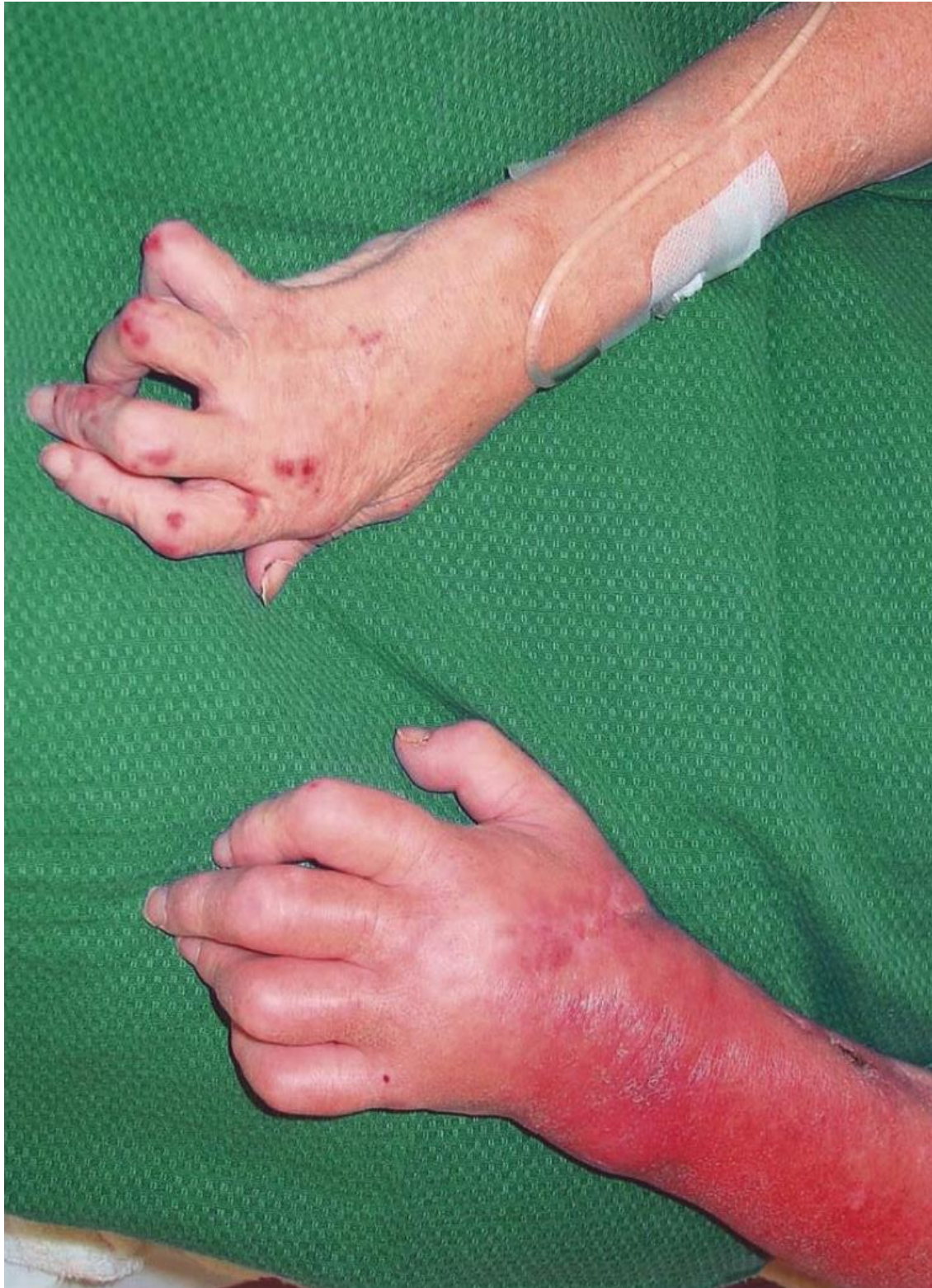

SAQ 2

A 54 year old woman presents to the ED with three days of painful swelling in her left wrist and hand. A clinical image of the patient's forearms is shown on the next page.

a. Describe and interpret the clinical image (6 Marks)

b. Outline your investigations & rational for investigation in this patient (4 Marks)

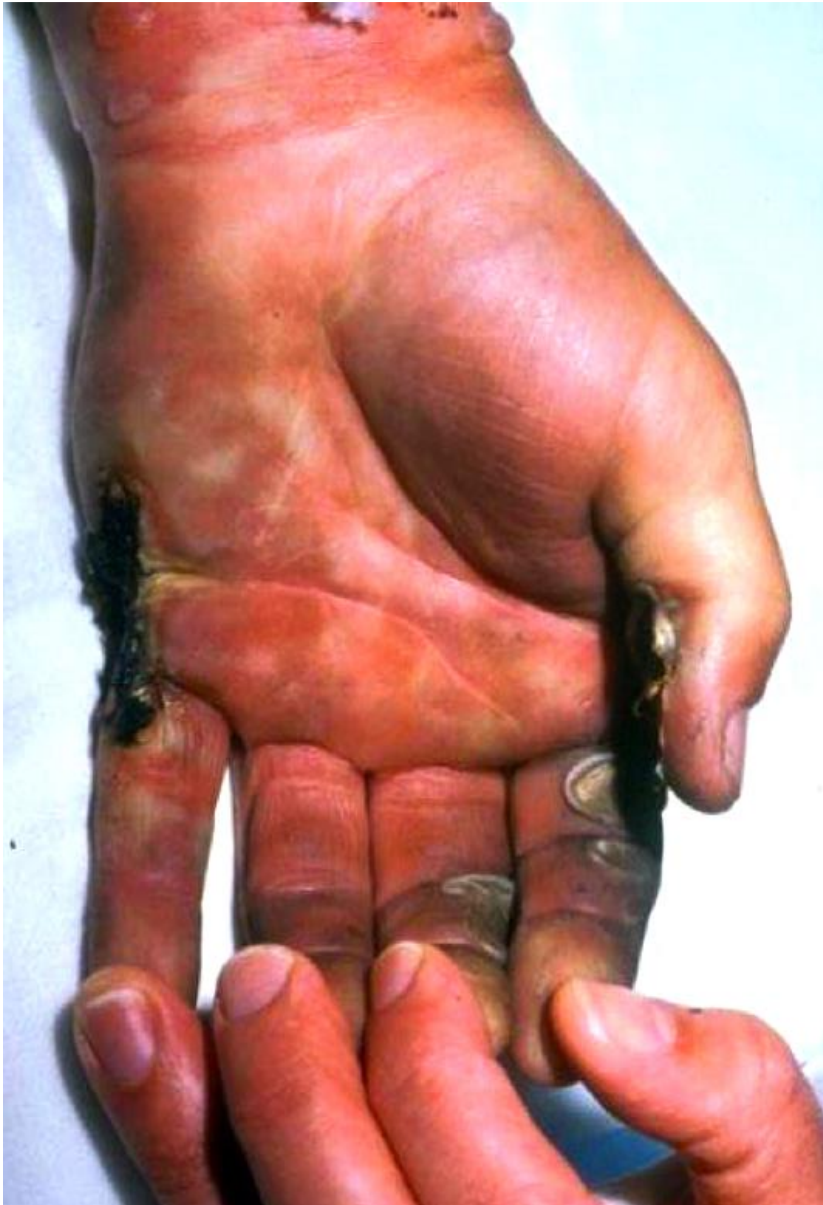

Question 3

A 35 year old man presents to your emergency department after a high voltage electrical injury.
A picture of the patient's hand is overleaf

a. Describe & interpret the clinical image? (4 Marks)

b. List the potential complications following this injury (6 Marks)



SAQ 4

You receive a Priority 1 call from the ambulance service. A 5 yr old boy is on route by ambulance post drowning in family home pool. ETA is 10 min.

a. What factors indicate a poor prognosis in this scenario ? (4 Marks)

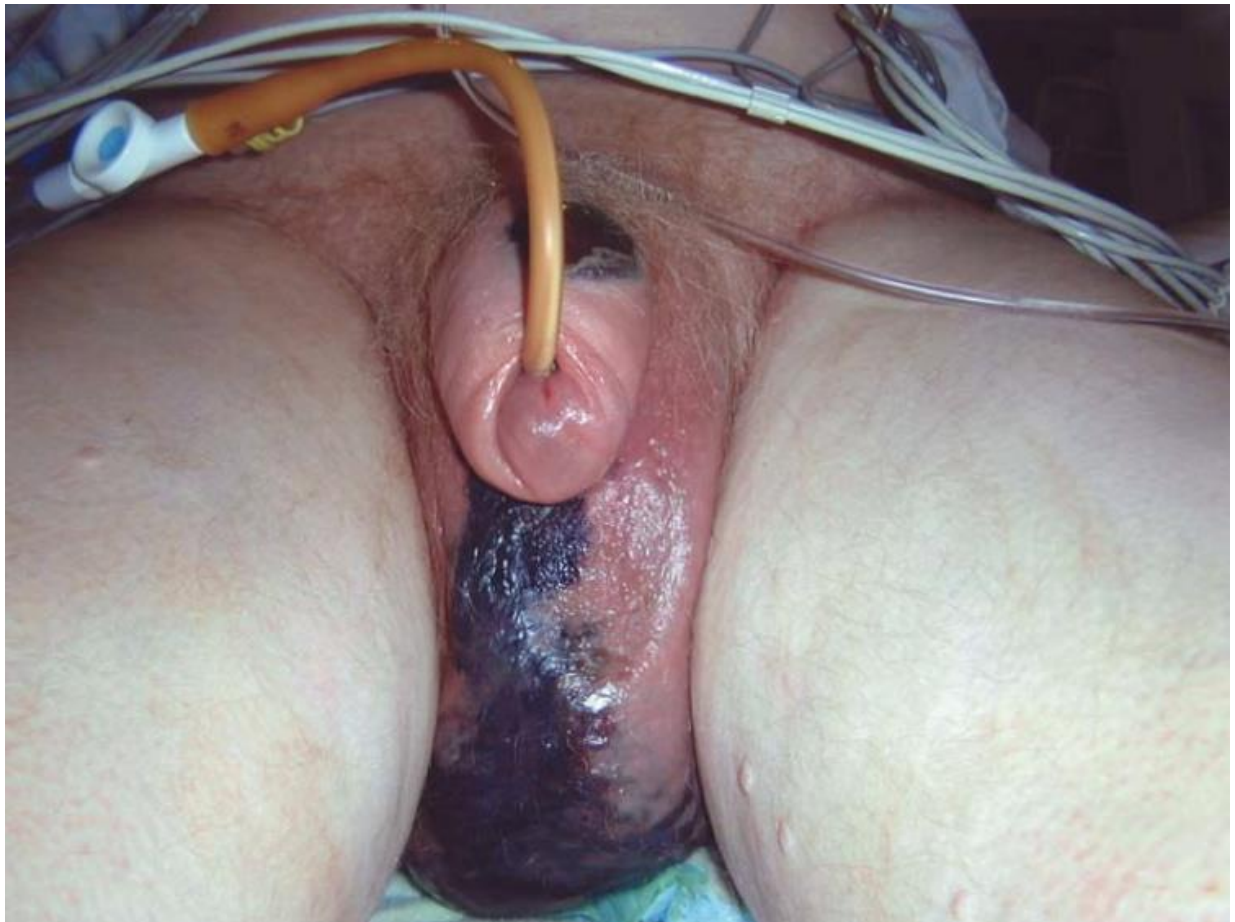b. Outline your preparation for the patient's arrival (6 marks) giving examples for each.

SAQ 5

A 40 year old man presents with delirium, scrotal pain and temperature of 39 °C.
A clinical image of the patient's perineum is on the next page.

a. Describe and interpret the clinical image (5 Marks)

b. Outline your management (5 Marks)



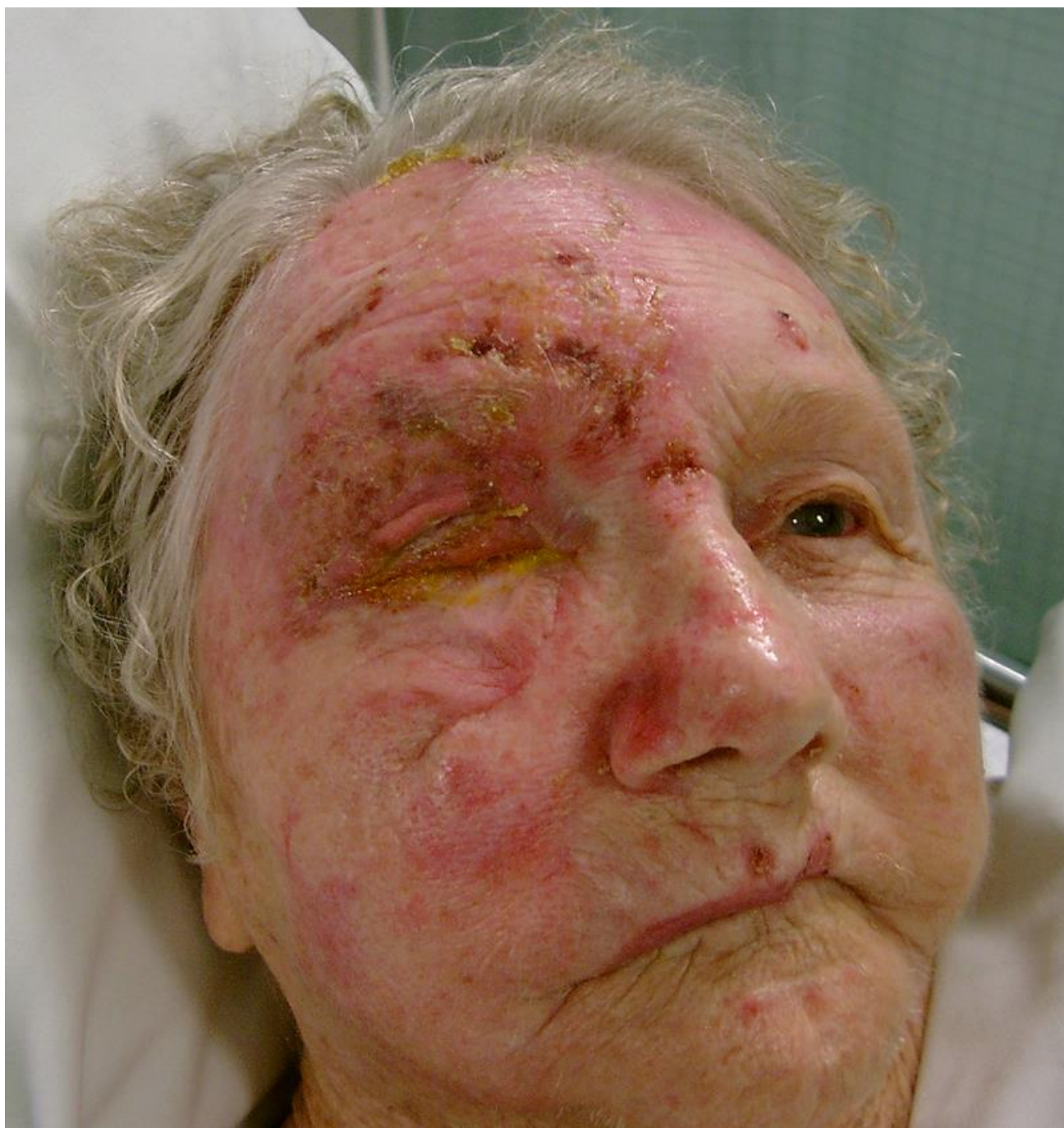SAQ 6

An elderly woman presents to your Emergency Department with a 2 day history of painful rash on her face. A clinical image of the patient's face can be found on the next page.

a. Describe and interpret the clinical image (4 Marks)

b. List 4 potential complications of this condition (4 Marks)

c. Outline your management (3 Marks)



SAQ 7

A obese but otherwise healthy 30 year old woman is brought to your emergency department suffering from shortness of breath after a 3 day viral prodrome. Her vital signs are:

HR 125 bpm
BP 80/60
RR 34

Temp 38.0 °C
Sats 85% on 8 L/min O₂

The patient's CXR is shown on the next page.

a. Describe the patient's CXR (1 Mark)

b. List 4 differentials for the patient's presentation and CXR findings (4 Marks)

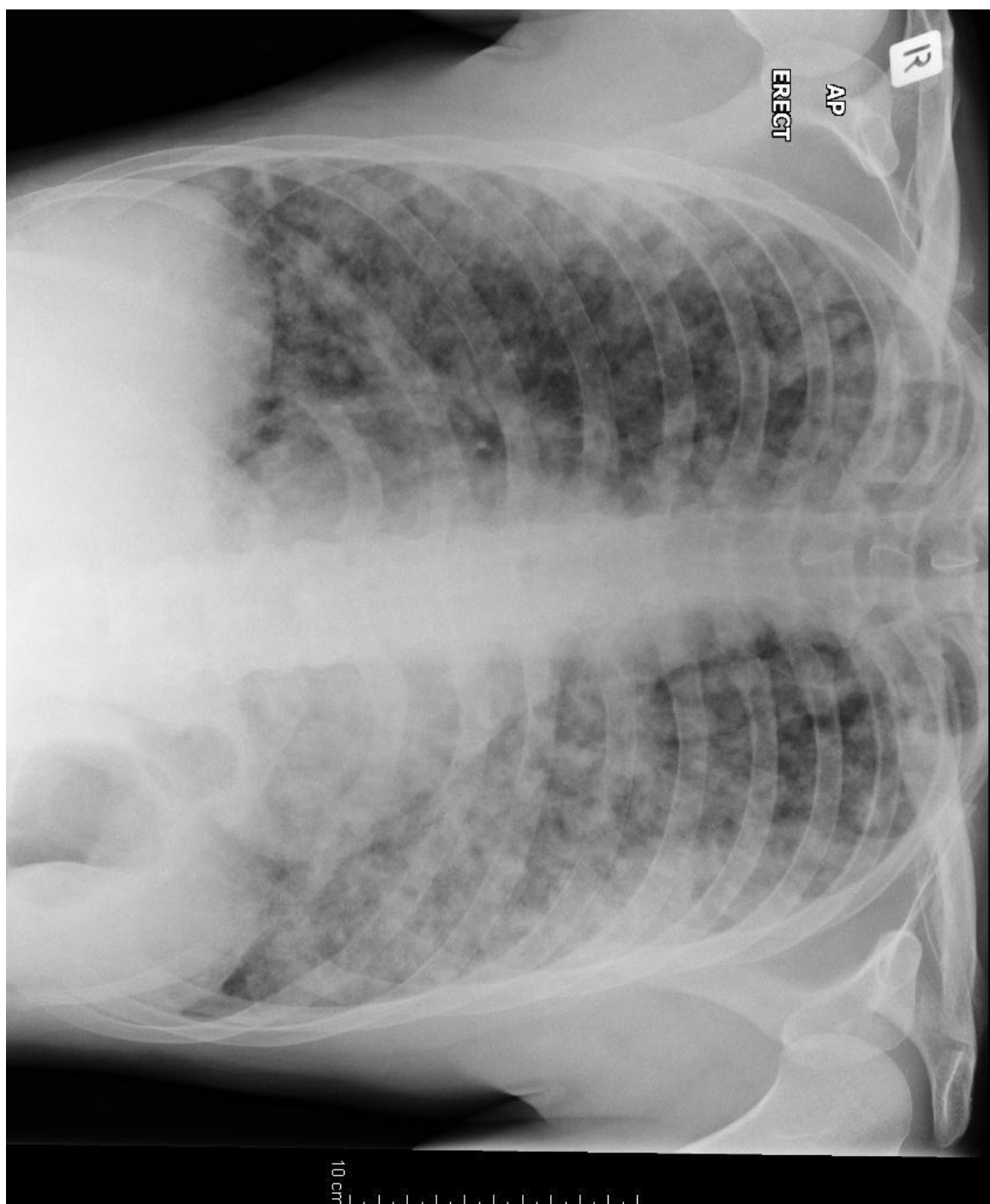
1.

2.

3.

4.

c. Outline your management (5 Marks)



SAQ 8

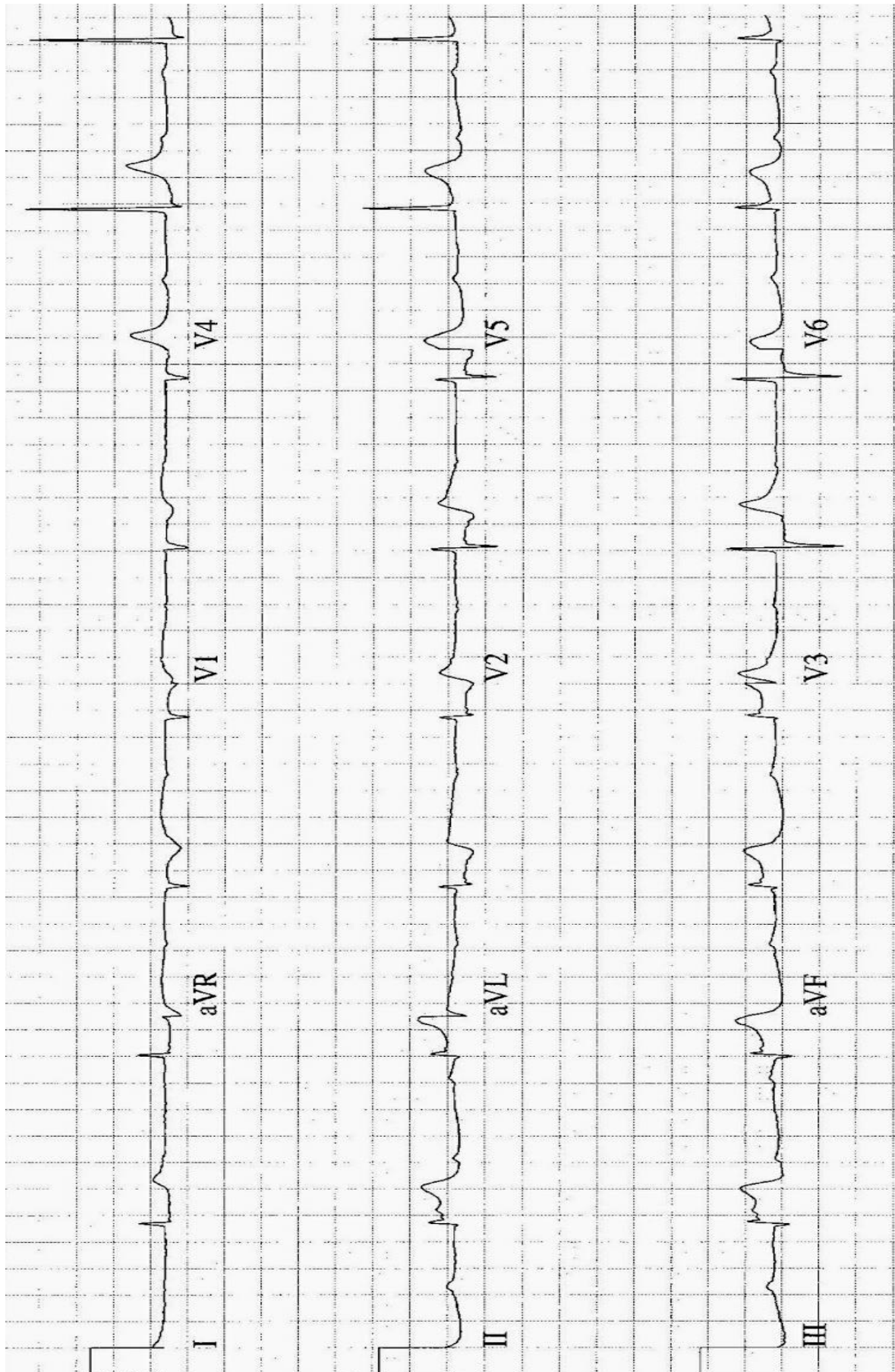
A 60 year old male presents to you Emergency Department complaining of chest pain for the last 2 hours. He has no known medication history and does not take any regular medications.

His ECG on arrival is below.

a. What is your interpretation of his ECG ? (3 Marks)

b. The patient's blood pressure is 80mmHg. Outline the key steps in managing his hypotension. (4 Marks)

c. The cardiology team have advised you to commence the patient on a vasoactive agent to improve his blood pressure. List 3 appropriate inotropes / vasopressors and their dosing below. (3 Marks)



SAQ 9

A 24 year old woman has just died in your ED despite active resuscitation after sustaining massive head injuries in a motor vehicle accident. Police are in attendance but her family members are unaware of the situation.

a) How will you break the news to the family? (6 marks)

b) In what circumstances must a death be reported to the coroner? (4 marks)

SAQ 10

A 4 year old boy presents to the ED with cough, stridor and fever

1. List four causes of stridor in this patient (4 marks)

2. List four features on history or examination that would make epiglottitis a more likely diagnosis (4 marks)

3. In a patient with suspect epiglottitis, what are your management priorities (2 marks)
