

SAQ 1

A 62 yr old male presents to your Emergency Department complaining of dyspnoea and headache. He is currently on chemotherapy.

Vital signs:

HR 85

Bp 124/76

Temp 36.3 °C

a. Describe & interpret the clinical image of the patient (2 Marks)

b. List 4 causes of this clinical picture (4 Marks)

1.

2.

3.

4.

c. List 8 side effects associated with chemotherapy (8 Marks)

1.

2.

3.

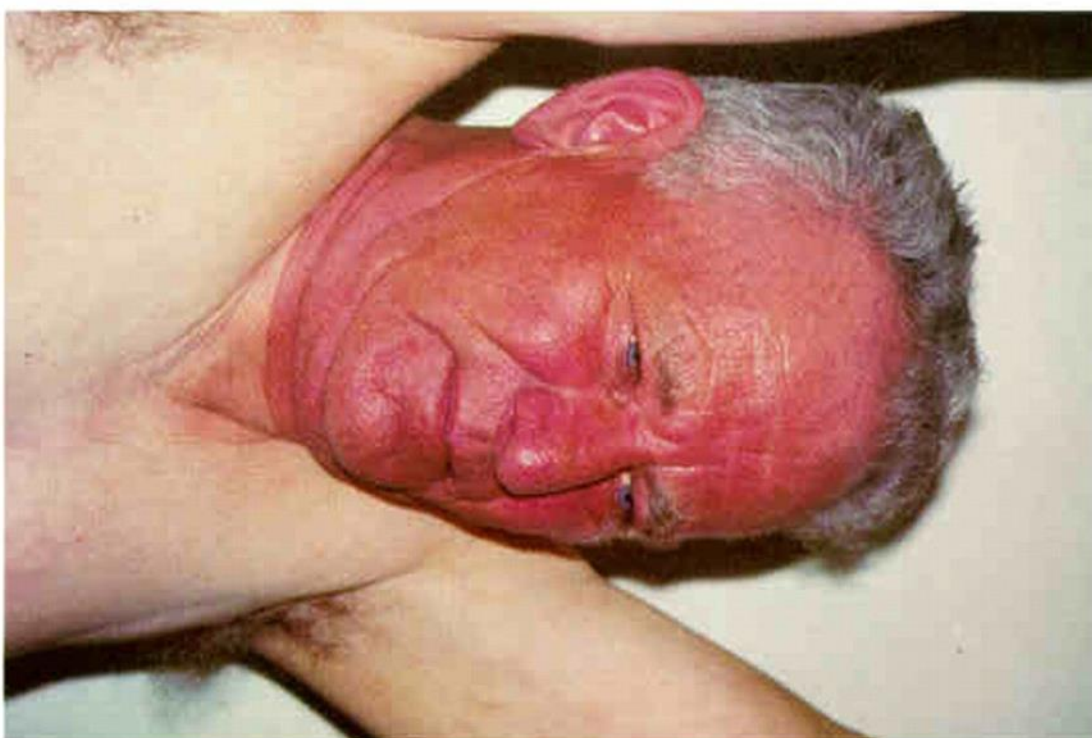
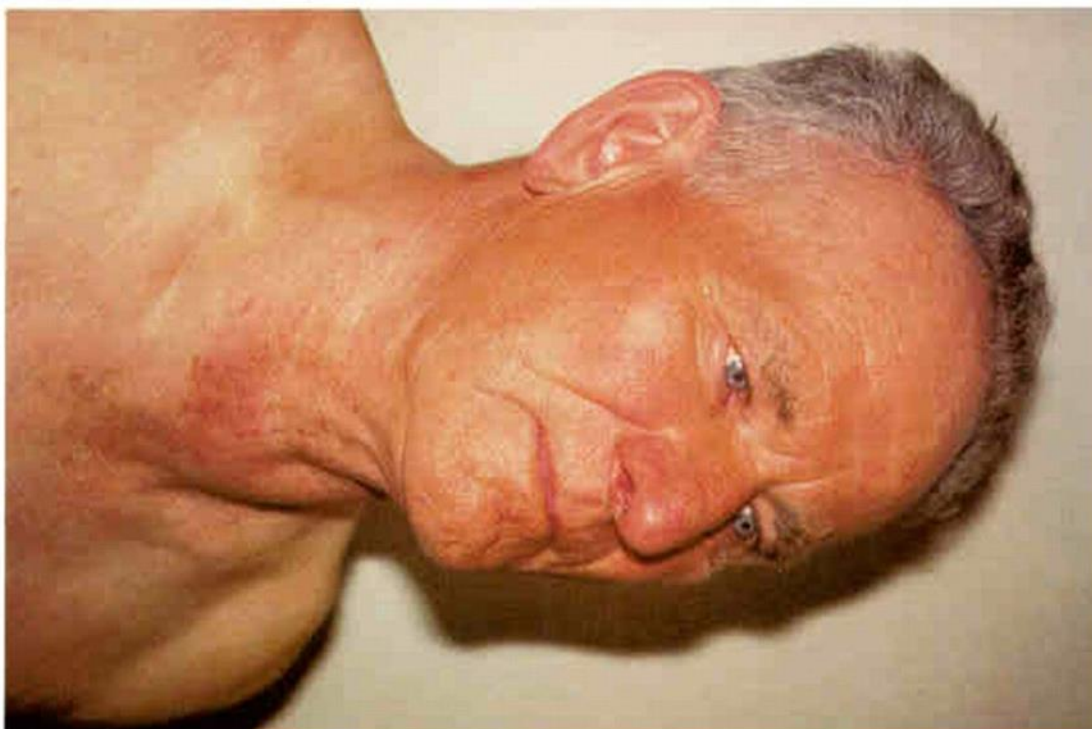
4.

5.

6.

7.

8.



SAQ 2

A mother has brought her 2 yr old son to your Emergency Department following a suspected seizure. He has been unwell for 2 days with a febrile illness. You suspect the child has had a febrile convulsion.

a. What is the frequency (in %) of febrile convulsion in children? (1 Mark)

b. List 4 features associated with a simple febrile convulsion (4 marks)

c. List 4 factors associated with an increased risk of a child having recurrent febrile convulsions (4 marks)

d. The patient's mother is concerned about the risk of her child developing epilepsy. List 3 factors associated with an increased risk of future afebrile convulsions. (3 marks)

SAQ 3

A GP has referred a 54 yr old male to your Emergency Department with pancreatitis. He has had 2 days of epigastric pain and vomiting. His serum lipase is 4300 [lab normal <60].

a. List 4 potential causes for this patient's pancreatitis (4 Marks)

b. List 4 potential complications from pancreatitis (4 Marks)

c. List 6 factors that suggest severe pancreatitis (6Marks)

SAQ 4

A mother has brought her 6 day old baby to your Emergency Department, she is concerned that her child has become increasingly jaundiced.

a. What percentage of term and pre-term babies develop jaundice in the first week of life? (2 Marks)

b. List 4 causes of neonatal unconjugated hyperbilirubinaemia (4 Marks)

c. List 2 causes of neonatal conjugated hyperbilirubinaemia (2 Marks)

d. List two factors associated with an increased risk of developing kernicterus (2 Marks)

SAQ 5

A 32 yr old female presents to your Emergency Department complaining of lower abdominal pain and vaginal discharge. She is sexually active and uses an IUCD as contraception.

Clinical examination reveals diffuse lower abdominal tenderness without peritonitis and adenexal tenderness

Vital signs

HR 85 bpm

BP 125 / 75

RR 16

Sats 98 % (Room air)

Temp 36.6 °C

Urinalysis

Leucocytes ++

Blood +

Nitrites -

B-HCG negative

a. List the three likely causative organisms (3 Marks)

b. List four complications of P.I.D (4 Marks)

c. What is the recommend empirical antibiotic strategy for this patient (4 Marks)

d. What other management consideration needs to be addressed (1 Mark)

SAQ 6

A 72yr old male presents to your Emergency Department following an episode of bright red rectal bleeding. He estimates he lost a cup of blood and felt dizzy during the episode. His medications include rivaroxaban, nifedipine, metoprolol and frusemide.

Vital signs:

HR 50

BP 90/60

RR 22

Sats 95% RA

Temp 36.2 °C

a. List 5 potential causes of his rectal bleed (5 Marks)

b. Outline your management of this patient (5 Marks)

SAQ 7

You have been invited to join your Emergency Departments Quality Improvement Workgroup

a. List the key steps in the Quality Improvement Cycle? (4 Marks)

b. List six clinical indicators used in Emergency Medicine to measure clinical care and outcomes. (6 Marks)

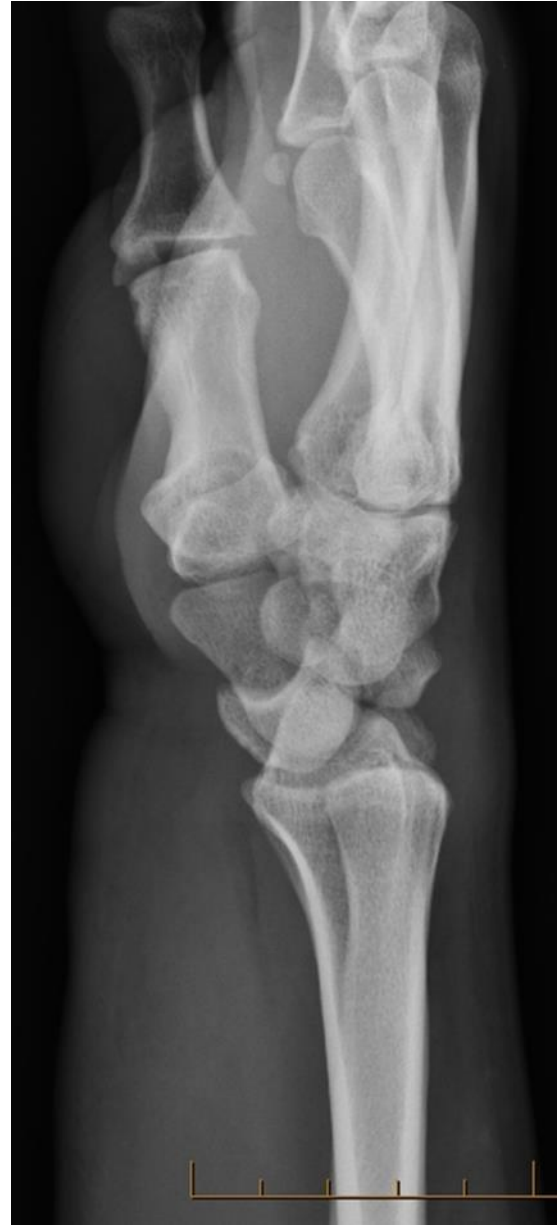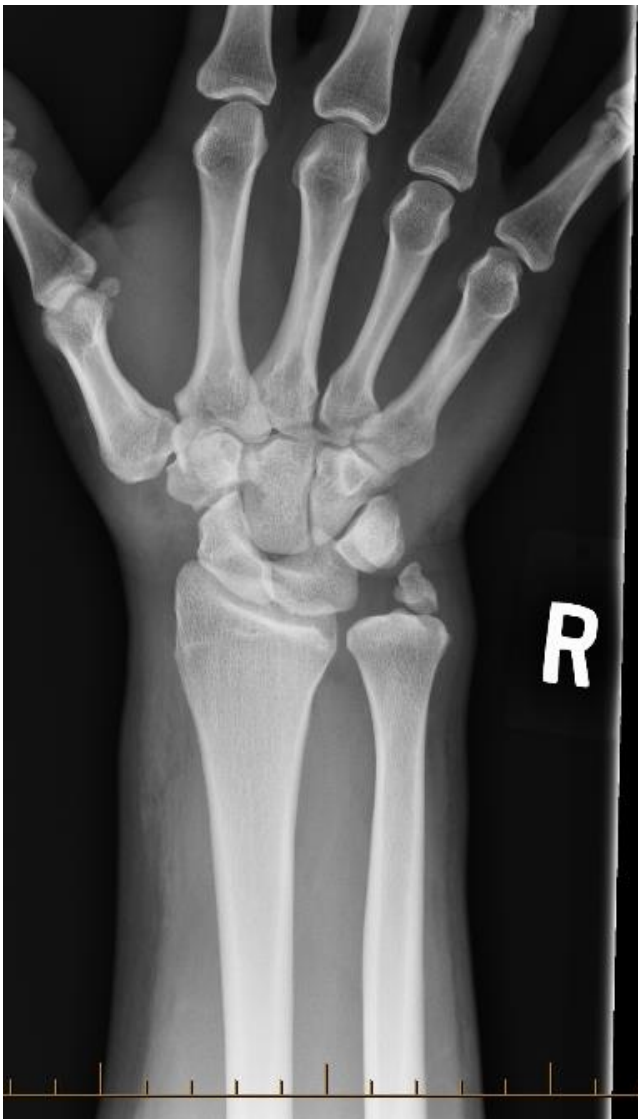SAQ 8

A 35 yr old male presents to your Emergency Department following a motorbike accident. He has an isolated right wrist injury.

a. List 4 abnormalities seen on his x-rays (4 Marks)

b. List 2 relevant negatives (2 Marks)

c. List 8 complications associated with this injury (4 Marks)



SAQ 9

A 26yr old male presents to your Emergency Department complaining of constipation for 4 days. He has been seen by the Emergency Department Intern and an abdominal x-ray has been performed.

a. Describe & interpret the patient's abdominal x-ray (4 Marks)

b. List 8 potential complications in this patient (4 Marks)

1.

2.

3.

4.

5.

6.

7.

8.

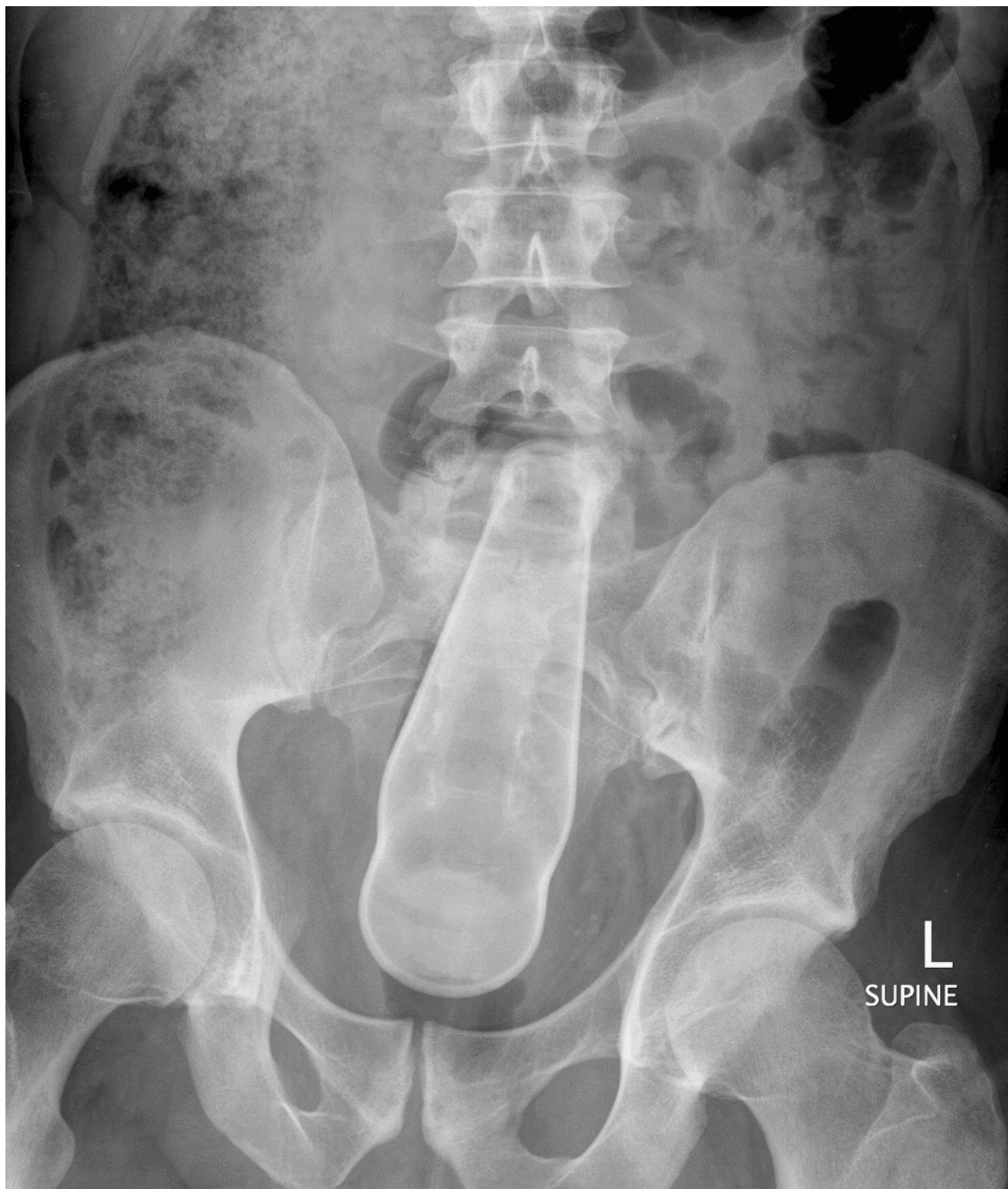c. List 4 indications for surgical referral for removal in patients with this presentation. (2 Marks)

1.

2.

3.

4.



SAQ 10

A 78 yr old male presents to your ED complaining of tongue swelling and dyspnoea.

Vital signs:

P 95

BP 168/79

RR 24

Sats 93% RA

Temp 36.8 °C

a. Describe the clinical image of the patient (3 Marks)

b. List 4 potential causes for this patient's condition (2 Marks)

1.

2.

3.

4.

