

Candidate name: _____

FELLOWSHIP TRIAL EXAMINATION

Paper 1 - Props

WRITTEN EXAMINATION

SHORT ANSWER QUESTIONS

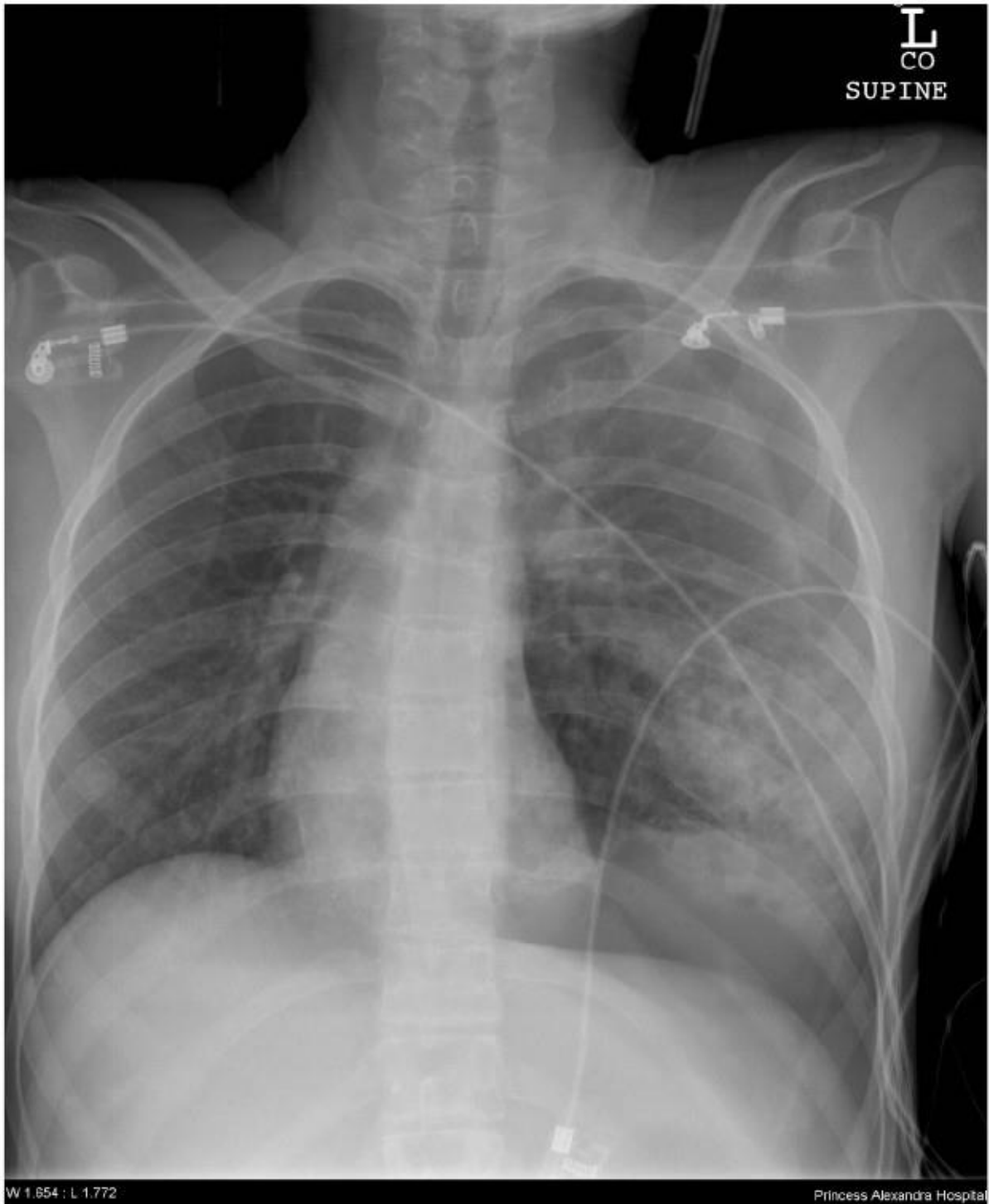
PROPS BOOKLET

Candidate initials: _____

SAQ 1

A 25 year old woman has been brought to the ED after a high speed head-on motor vehicle accident.

Her initial chest x-ray is given below.

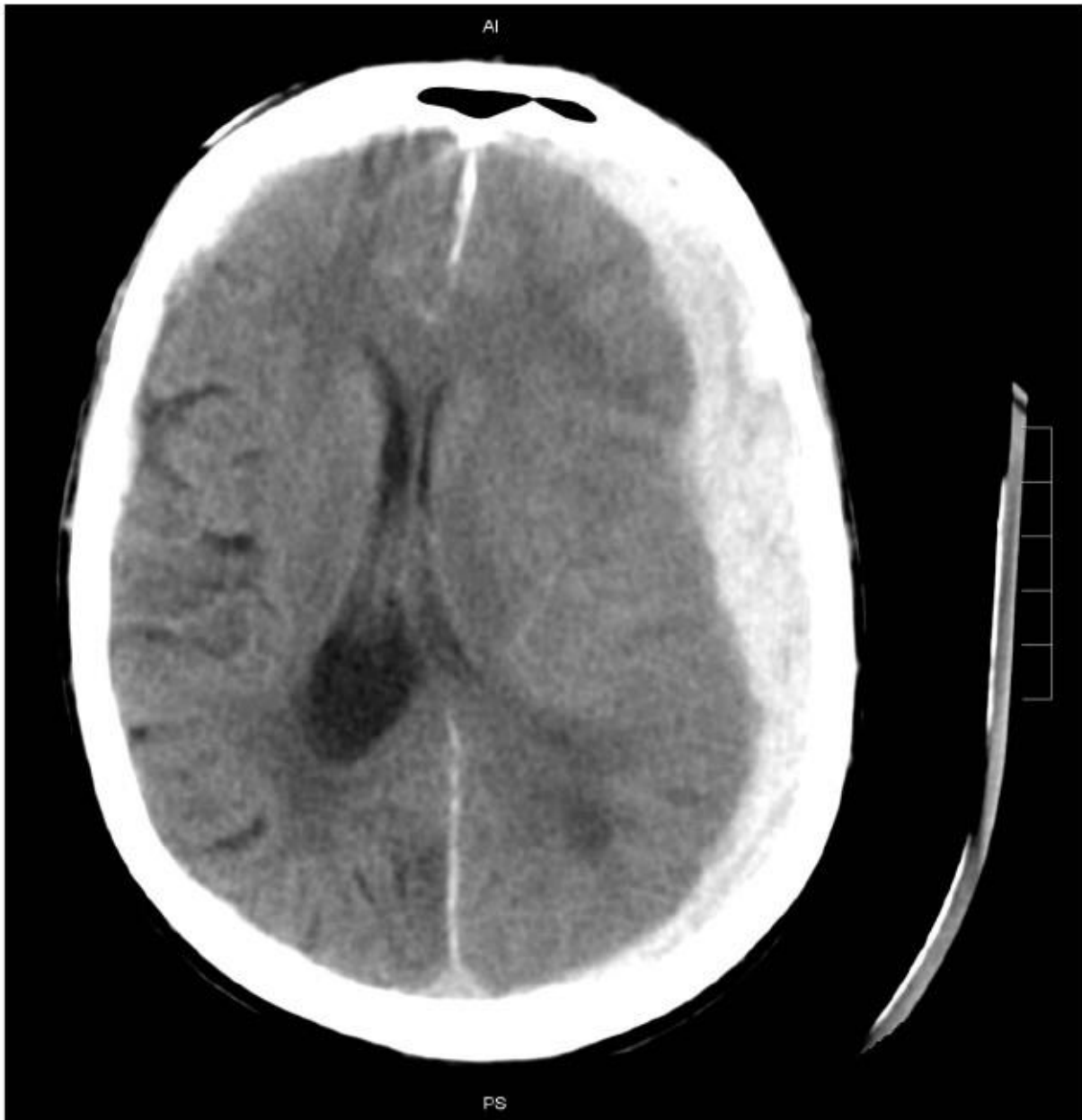

Candidate initials: _____

SAQ 1 (continued)

The patient has undergone CT scanning to delineate her injuries.

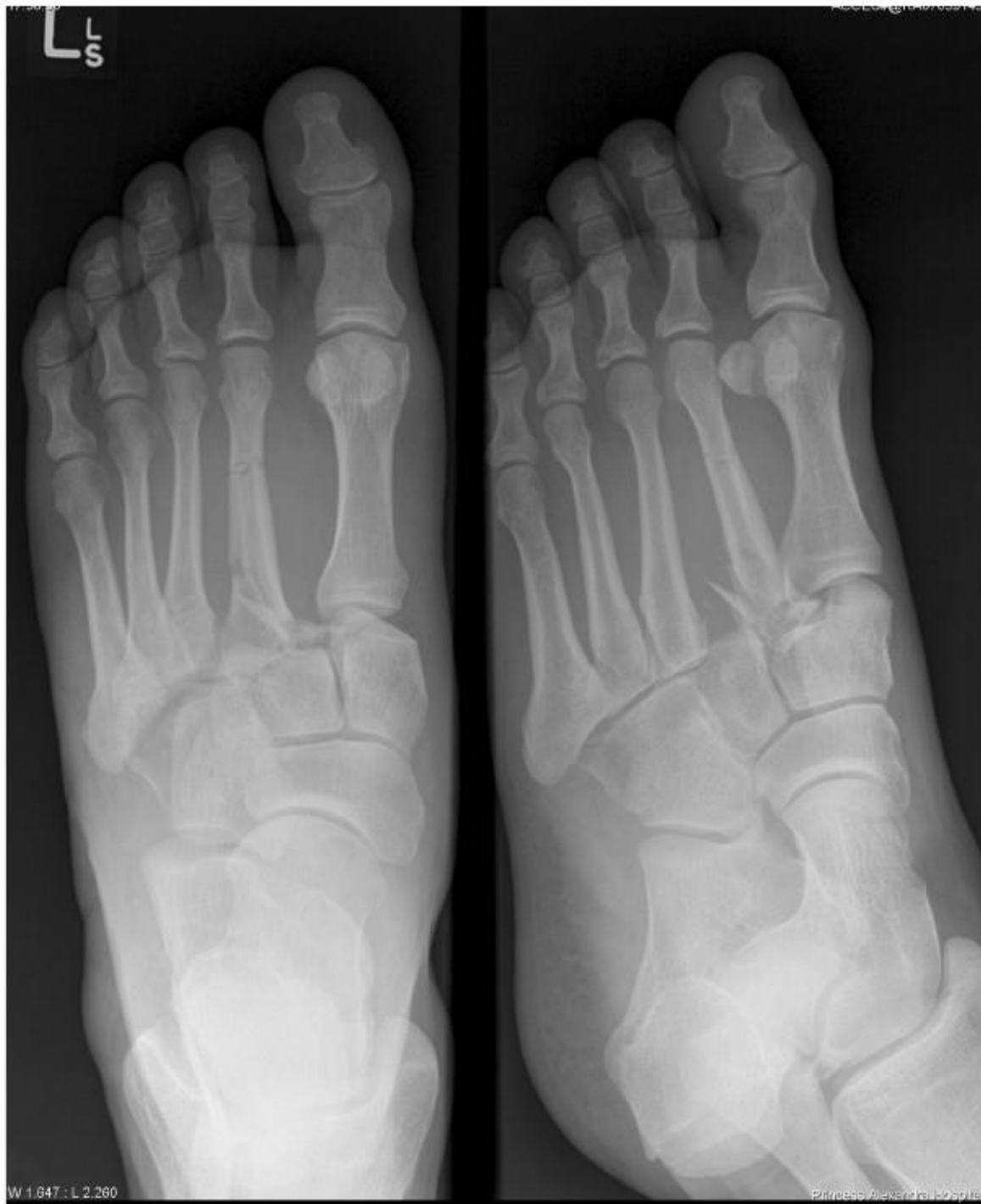A slice from her CT head is provided.



SAQ 2

A 30 year old man has presented to the ED with a painful, swollen left foot after jumping over a high fence. There are no other injuries.

His x-rays are provided.



Candidate initials: _____

SAQ 3

A 41 year old itinerant alcoholic has been brought to the ED with severe epigastric abdominal pain and vomiting.

His arterial blood gas, taken on room air, is provided.

	Result	Units	Reference Range
pH	7.17		(7.35 – 7.45)
pCO ₂	30	mmHg	(35 – 45)
pO ₂	98	mmHg	(80 – 100)
HCO ₃	11	mmol/L	(18 – 26)
Na	117	mmol/L	(135 – 145)
K	3.5	mmol/L	(3.2 – 4.5)
Cl	64	mmol/L	(100 – 110)
Ca (ionised)	0.74	mmol/L	(1.15 – 1.32)
Lactate	8.1	mmol/L	(0.5 – 2.2)
Glucose	34.2	mmol/L	(3.0 – 7.8)

Candidate initials: _____

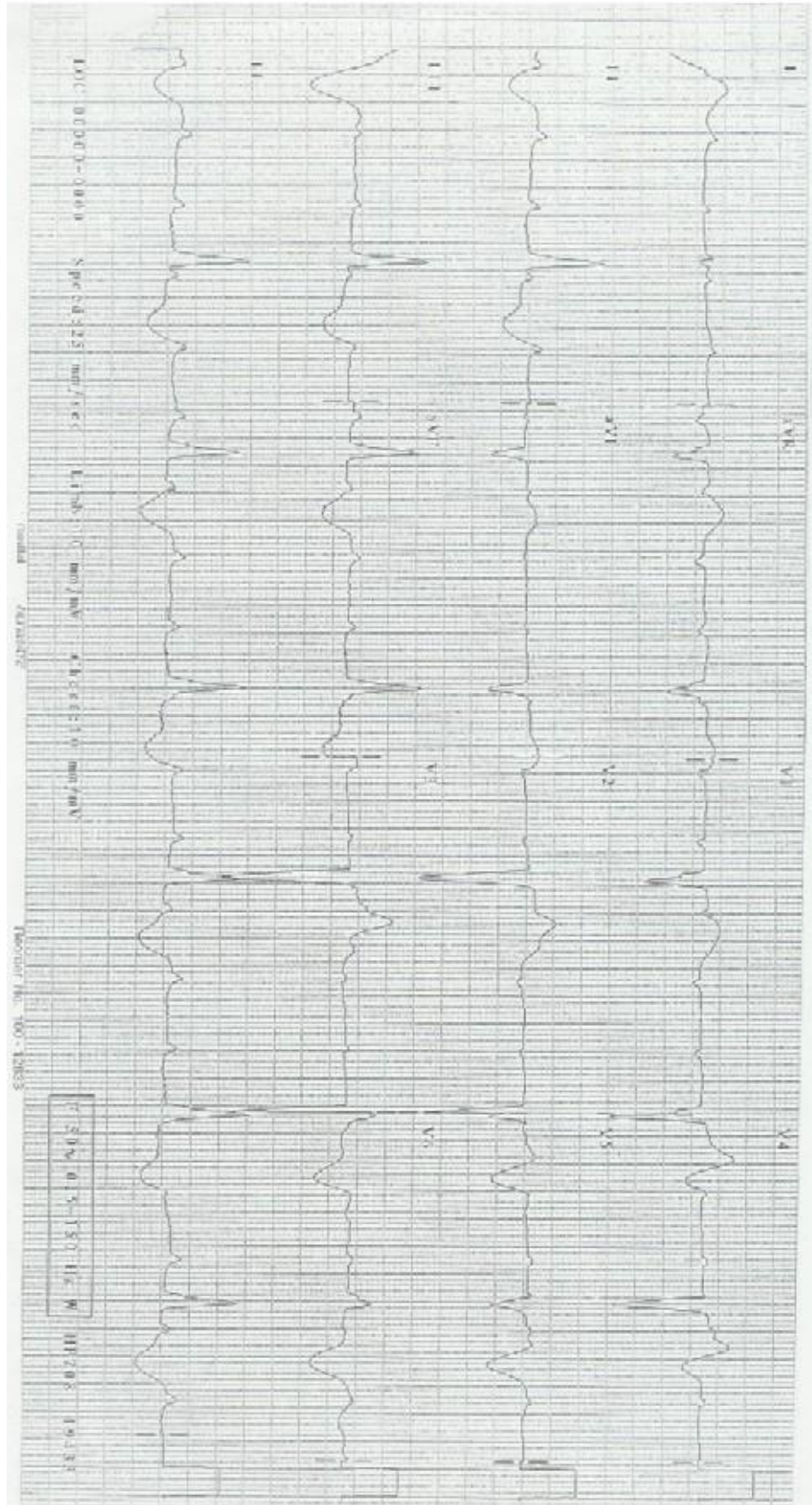
SAQ 4 – NO PROP

SAQ 5 – NO PROP

Candidate initials: _____

SAQ 6

A 70 year old man has presented to the ED after a syncopal episode.



Candidate initials: _____

SAQ 7 – NO PROP

SAQ 8 – NO PROP

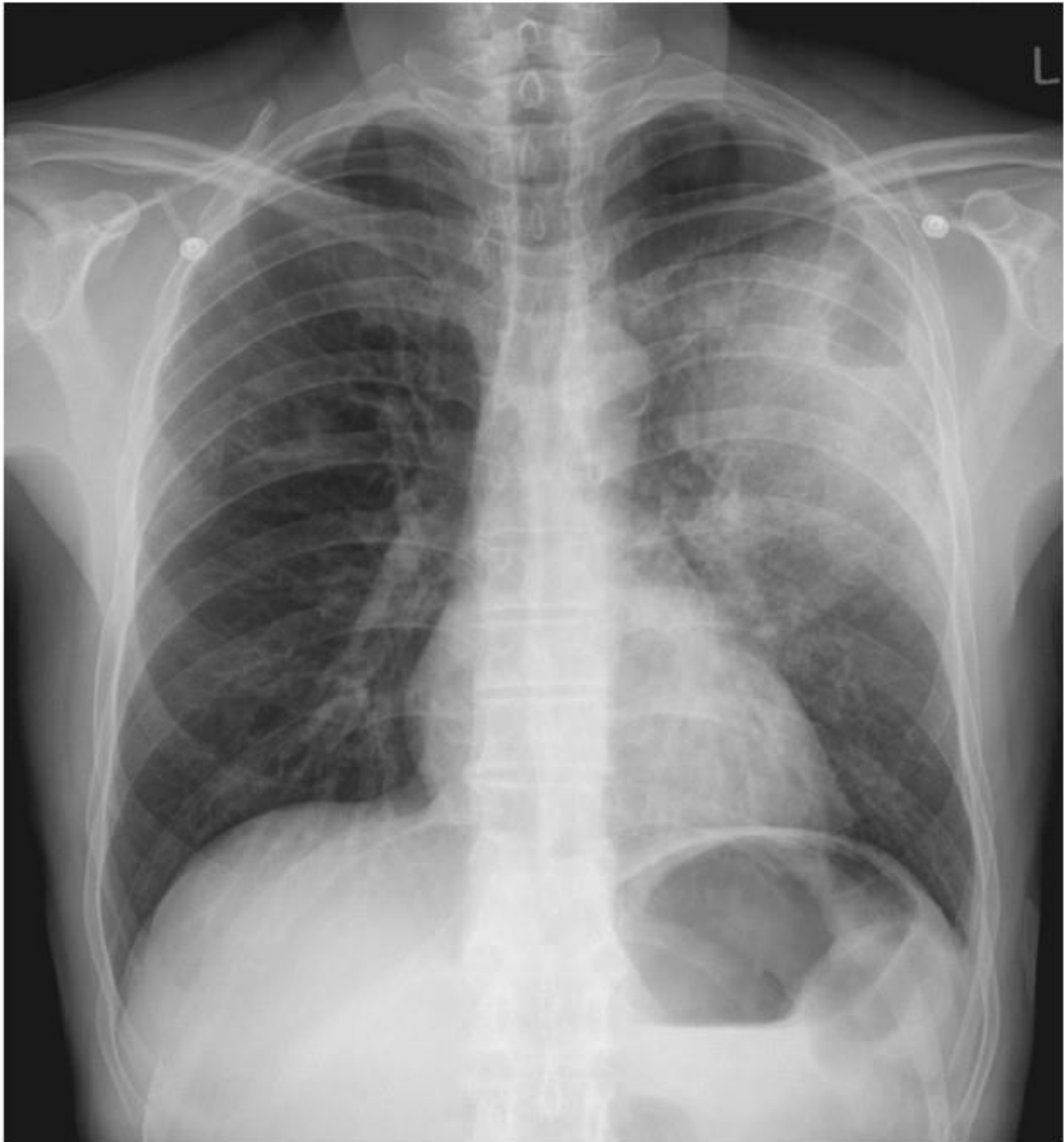
SAQ 9 – NO PROP

Candidate initials: _____

SAQ 10

A 65 year old man has presented to the ED with shortness of breath.

His chest x-ray is provided.

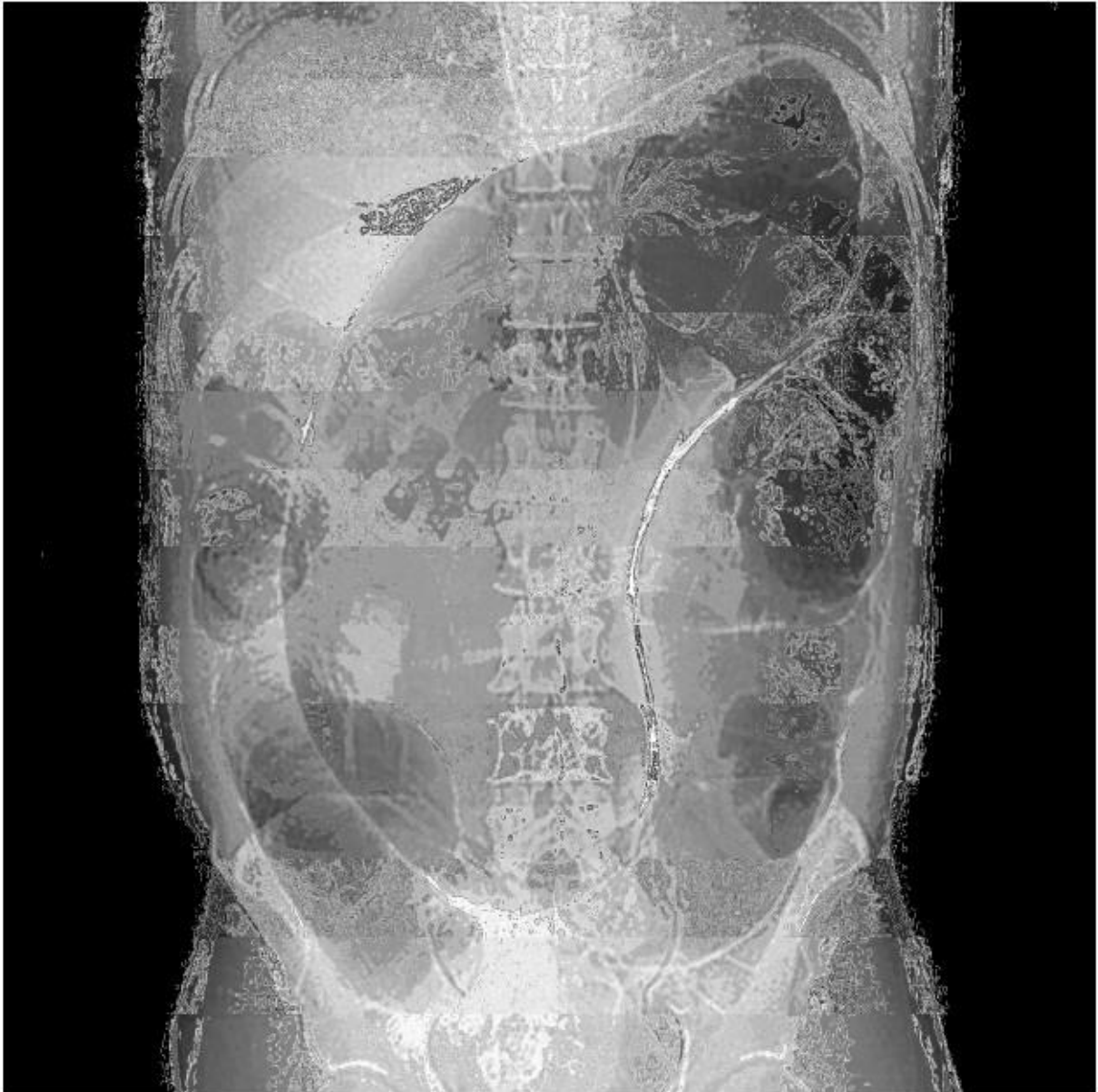

Candidate initials: _____

SAQ 11

A 75 year old man has been brought to the ED from his high level care nursing home with abdominal pain.

His abdominal x-ray is provided.



Candidate initials: _____

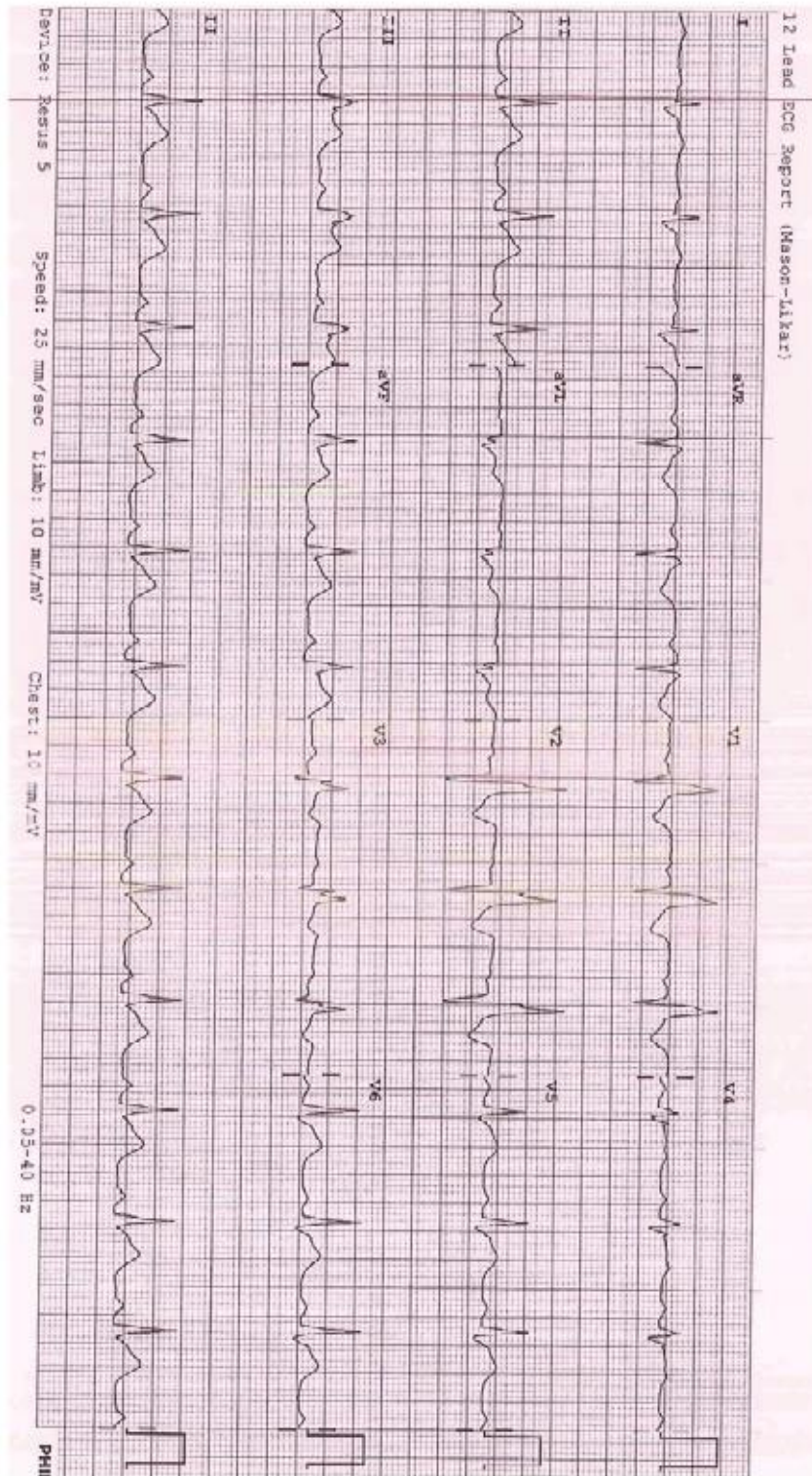
SAQ 12 – NO PROP

SAQ 13

A 56 year old woman has presented to your rural ED with 1 hour of central chest pain. The nearest tertiary centre is 3 hours away.

Her significant history is a myocardial infarction 2 years ago.

Her ECG is provided.



Candidate initials: _____

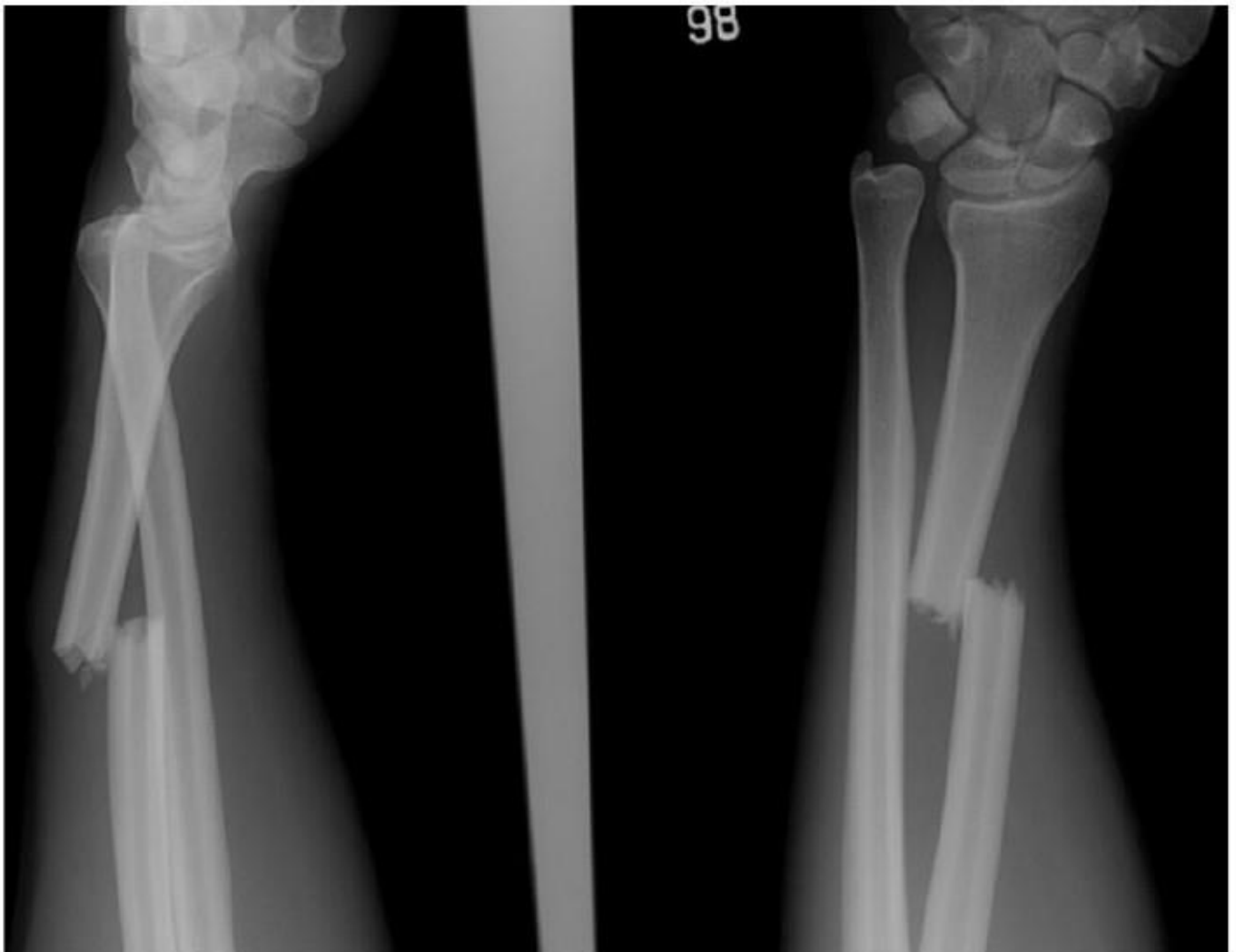
SAQ 14 – NO PROP

Candidate initials: _____

SAQ 15

A 20 year old man has presented to the ED after falling off a wall on to his right hand.

The x-rays of his right forearm are provided.

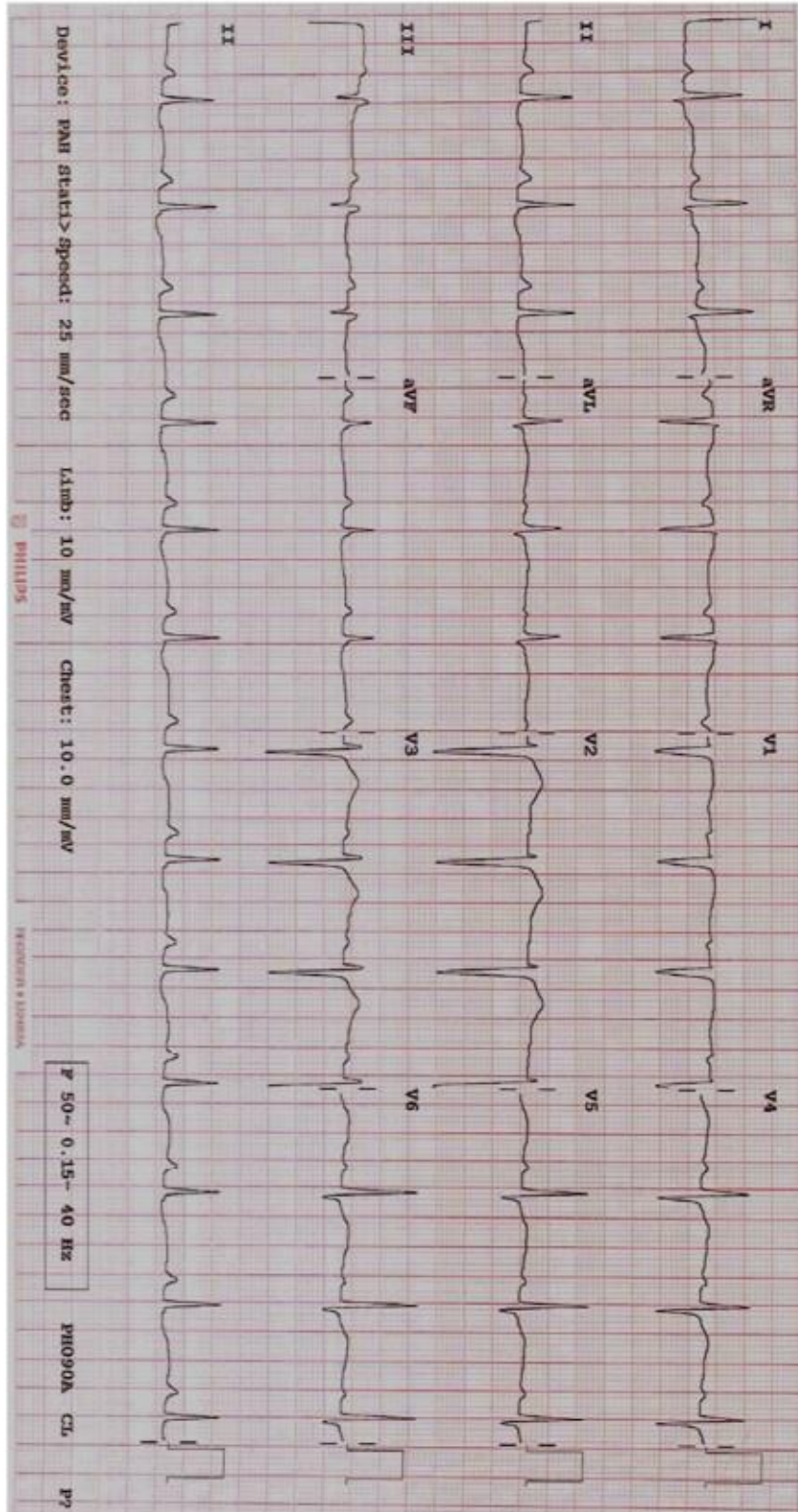


Candidate initials: _____

SAQ 16

A 36 year old man with a history of schizoaffective disorder has presented following a large overdose of citalopram.

His ECG is provided.

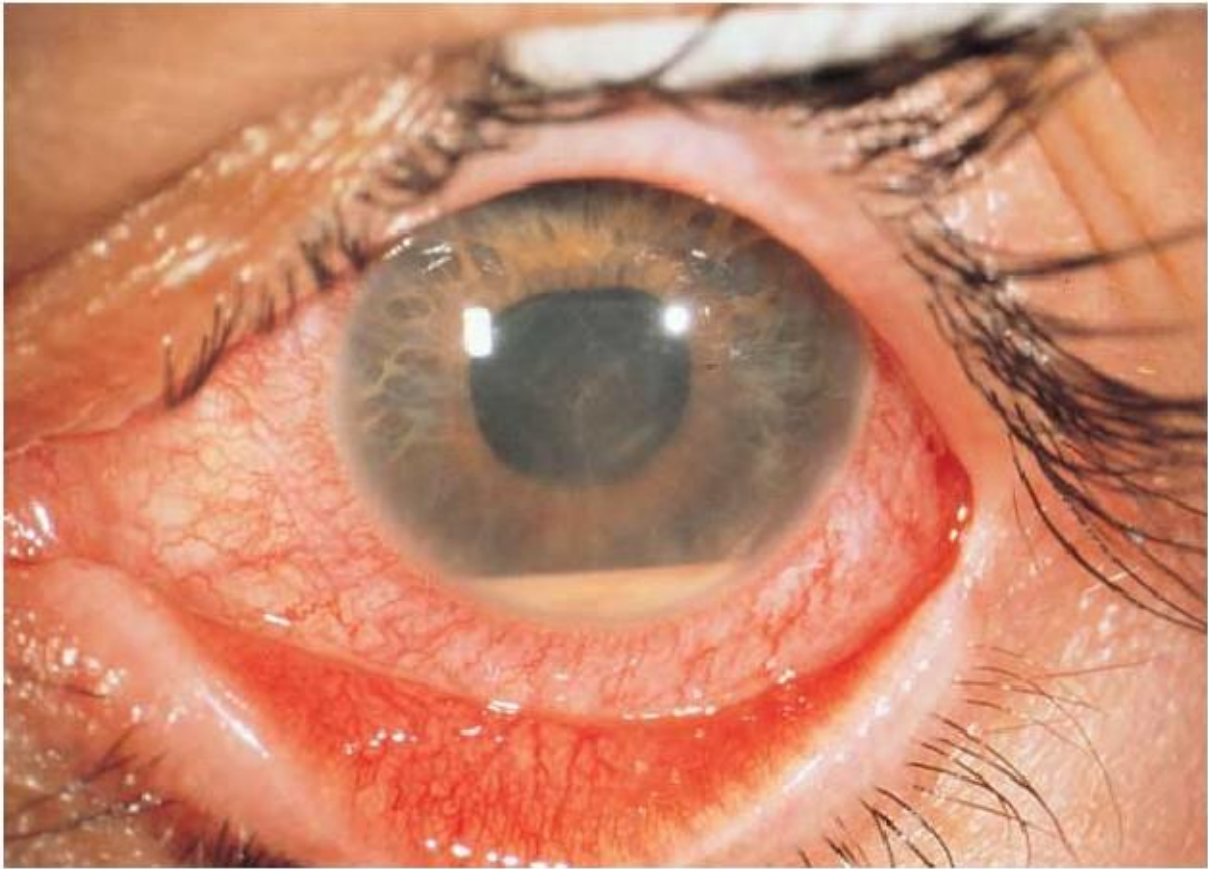

Candidate initials: _____

SAQ 17

A 25 year old woman has presented to the ED with a painful left eye.

Her clinical photograph is provided.



Candidate initials: _____

SAQ 18 – NO PROP

SAQ 19 – NO PROP

SAQ 20 – NO PROP

SAQ 21

Your registrar has called you to resus to help with a patient. An 18 year old male (body weight 80kg) presented in diabetic ketoacidosis, complicated by a prolonged generalised seizure. He has been intubated for airway protection and is currently being sedated and mechanically ventilated, awaiting ICU review.

An arterial blood gas, taken with FiO_2 1.0, is provided.

	Result		Reference
pH	7.02		7.35-7.45
PCO ₂	60	mmHg	30-40
PO ₂	200	mmHg	60-100
HCO ₃	11	mmol/L	22-31
BE	15		-3 – +3
Hb	155	mmol/L	120-165
Na	125	mmol/L	135-145
K	6.5	mmol/L	3.5-5.0
Cl	86	mmol/L	98-110
Gluc	35	mmol/L	3.5- 5.5
Lactate	2.5	mmol/L	<2

Candidate initials: _____

SAQ 22 – NO PROP

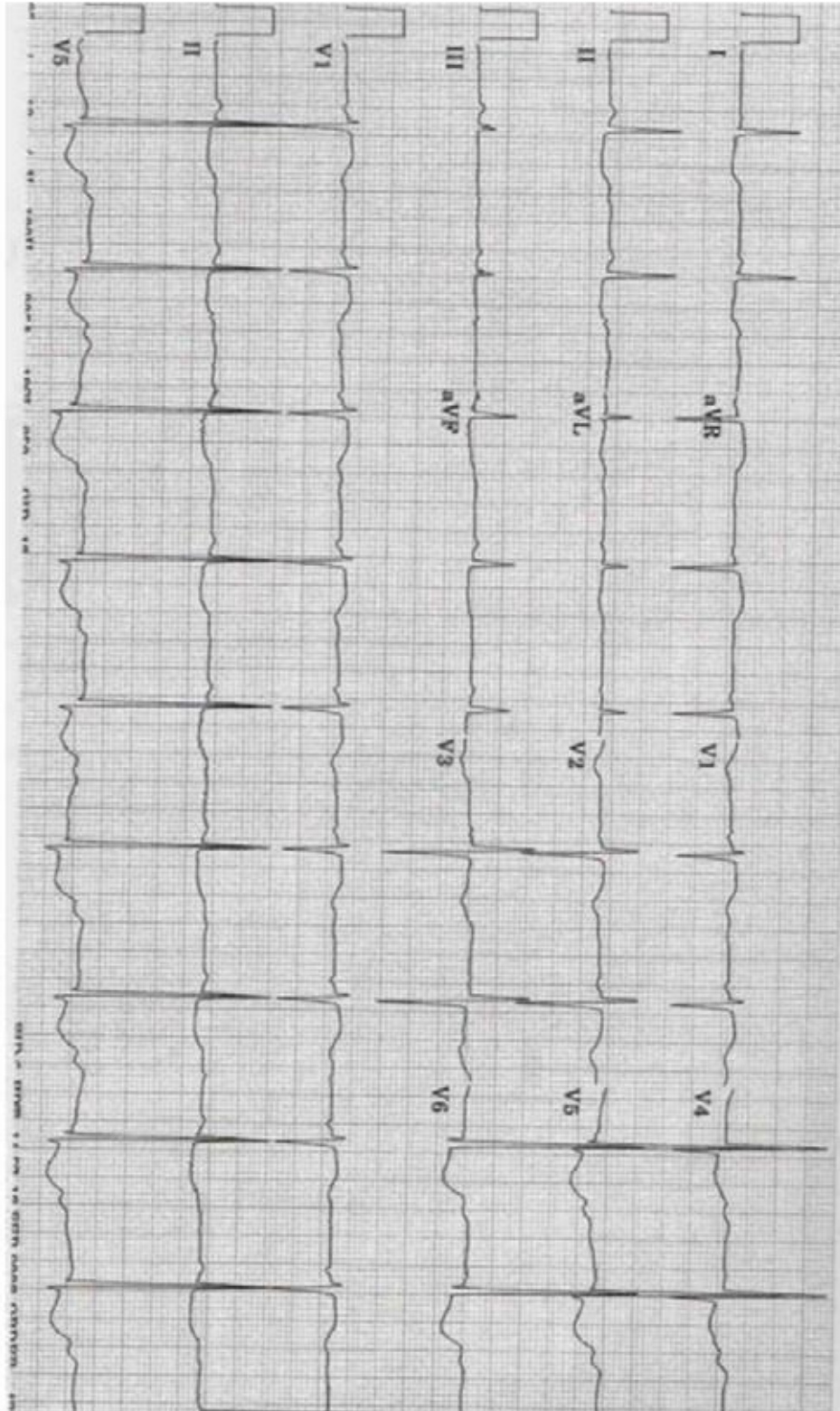
SAQ 23 – NO PROP

Candidate initials: _____

SAQ 24

An 18 year old girl is brought to ED after a collapse. She has a history of anorexia nervosa.

Her ECG is provided.



Candidate initials: _____

SAQ 25 – NO PROP

SAQ 26 – NO PROP

SAQ 27 – NO PROP