

Candidate name: \_\_\_\_\_

FELLOWSHIP TRIAL EXAMINATION

Paper 2 - Props

WRITTEN EXAMINATION

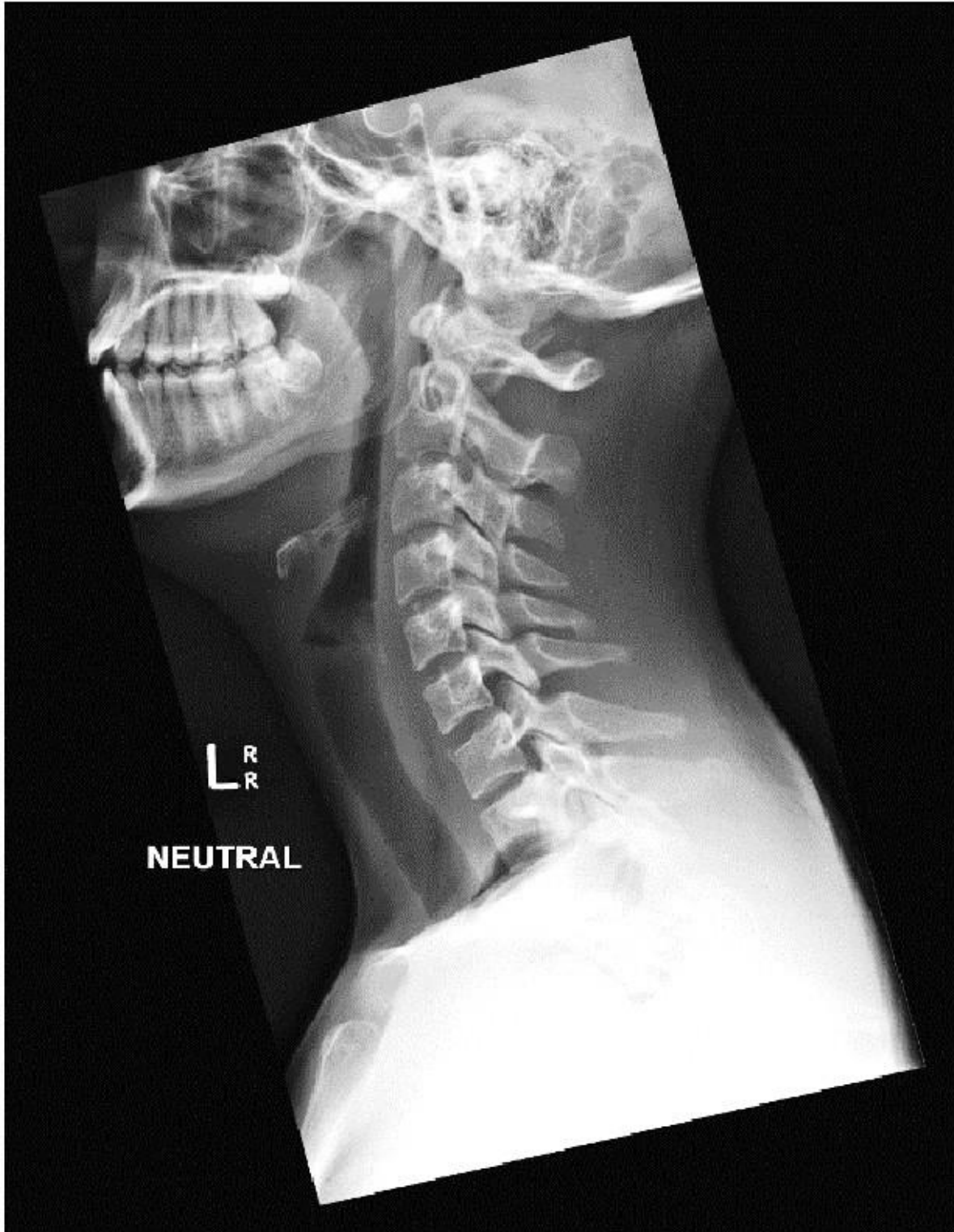
SHORT ANSWER QUESTIONS

**PROPS  
BOOKLET**

Q4

A 25 year old woman has been brought to the ED with neck pain after falling off a trampoline.

Her cervical spine x-ray is given below.



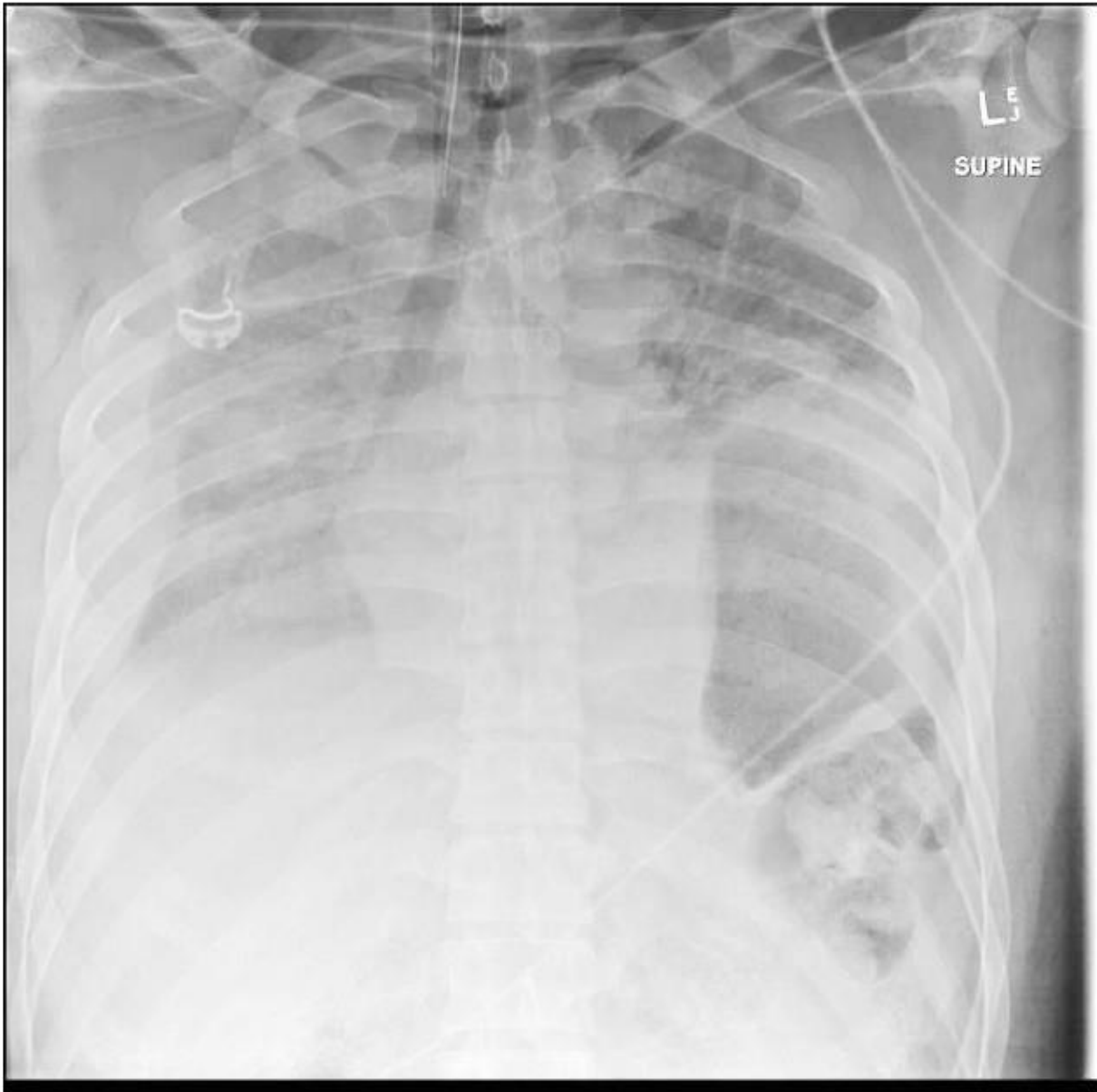Candidate initials: \_\_\_\_\_

Q10

A 32 year old man has been brought to the ED after a high speed motor vehicle accident.

He was intubated in the field due to severe respiratory distress. There is no evidence of head injury.

His initial chest x-ray is given below.



Candidate initials: \_\_\_\_\_

Q10 (continued)

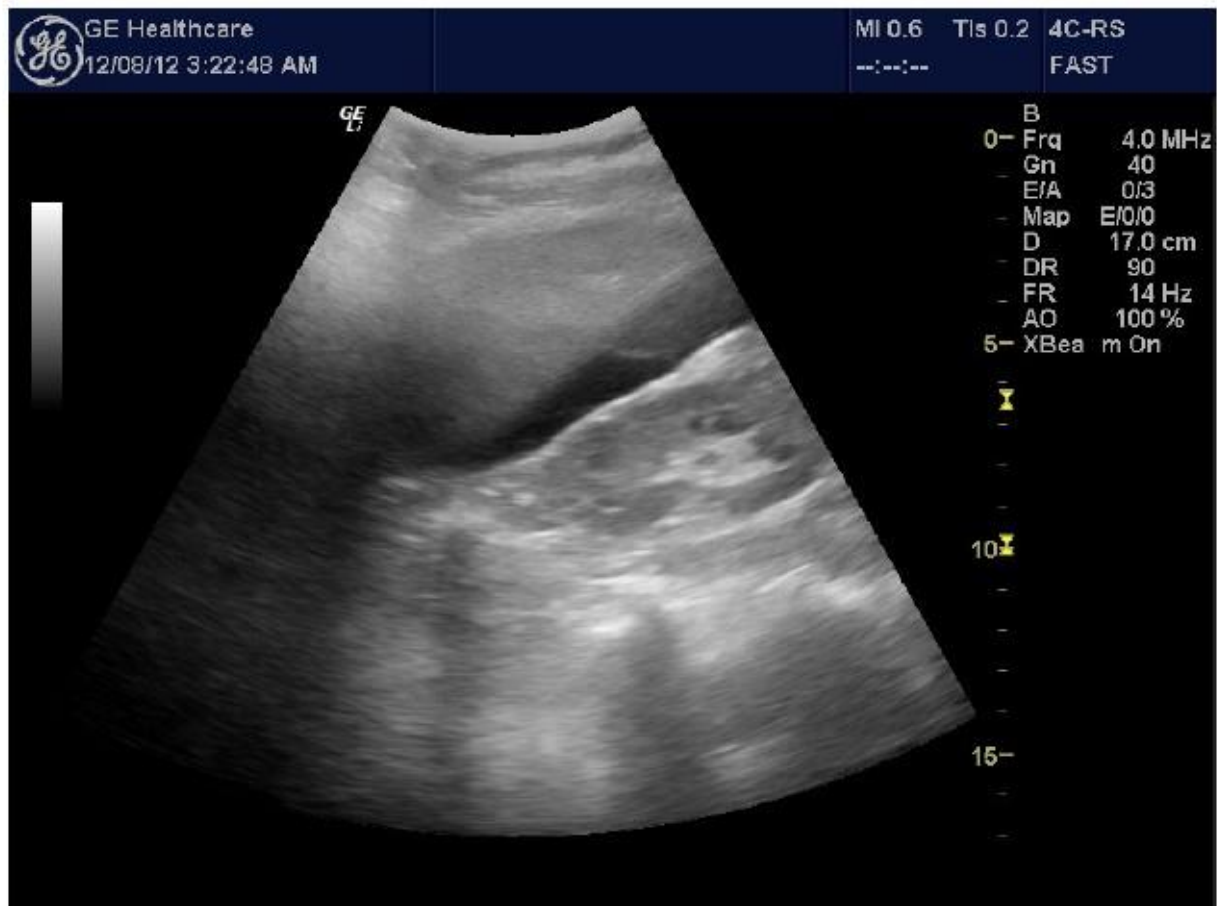
The patient looks pale and sweaty.

His vital signs are:

Pulse	140	/min
BP	65/45	mmHg
O2 sats	92%	FiO2 1.0

The pelvic x-ray is normal. There are no long bone injuries.

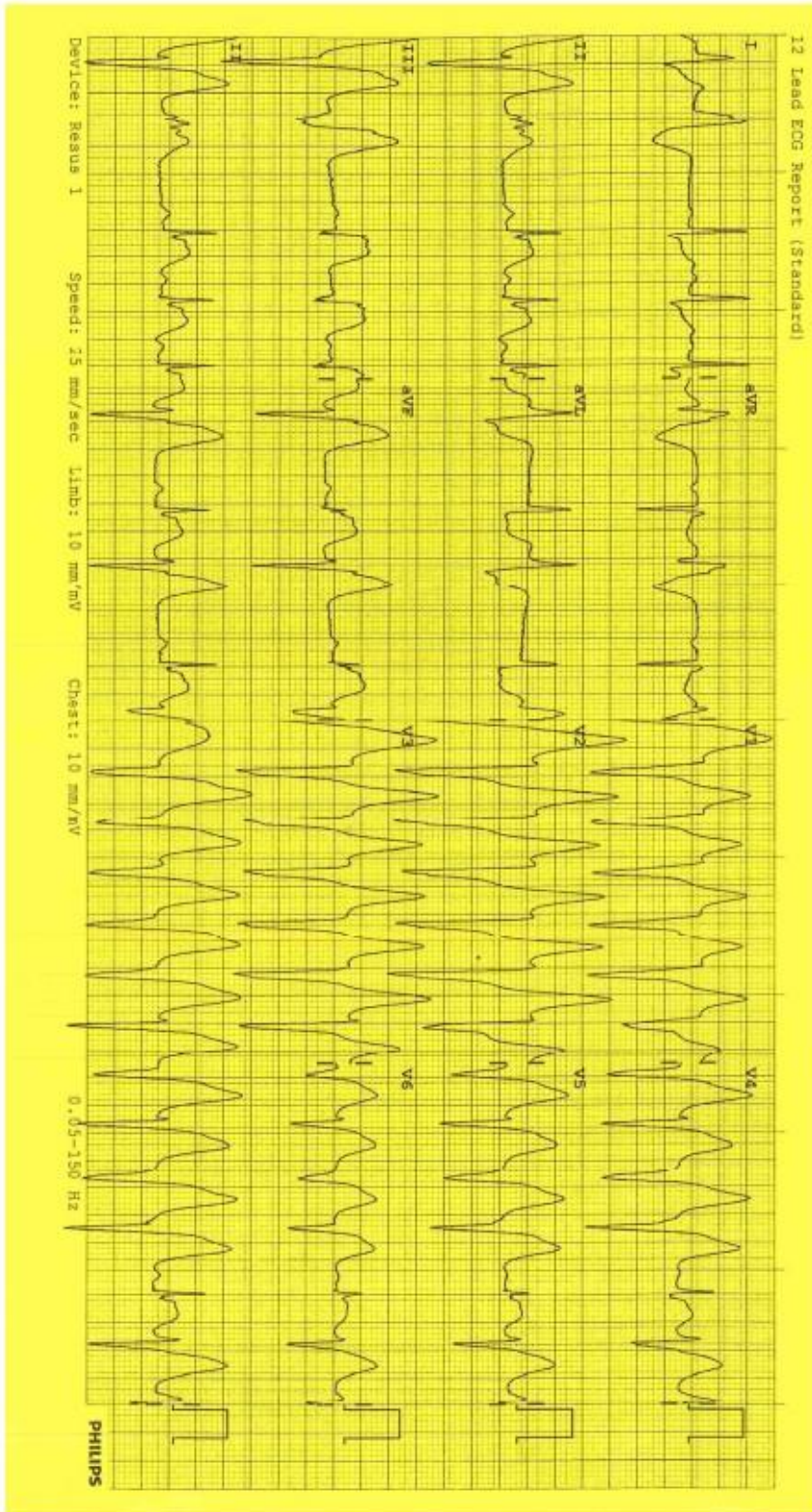
FAST scan imaging from the right upper quadrant is provided below.



Q11

A 45 year old man has self-presented to your tertiary ED with 2 hours of central chest pain.

His ECG is given below.

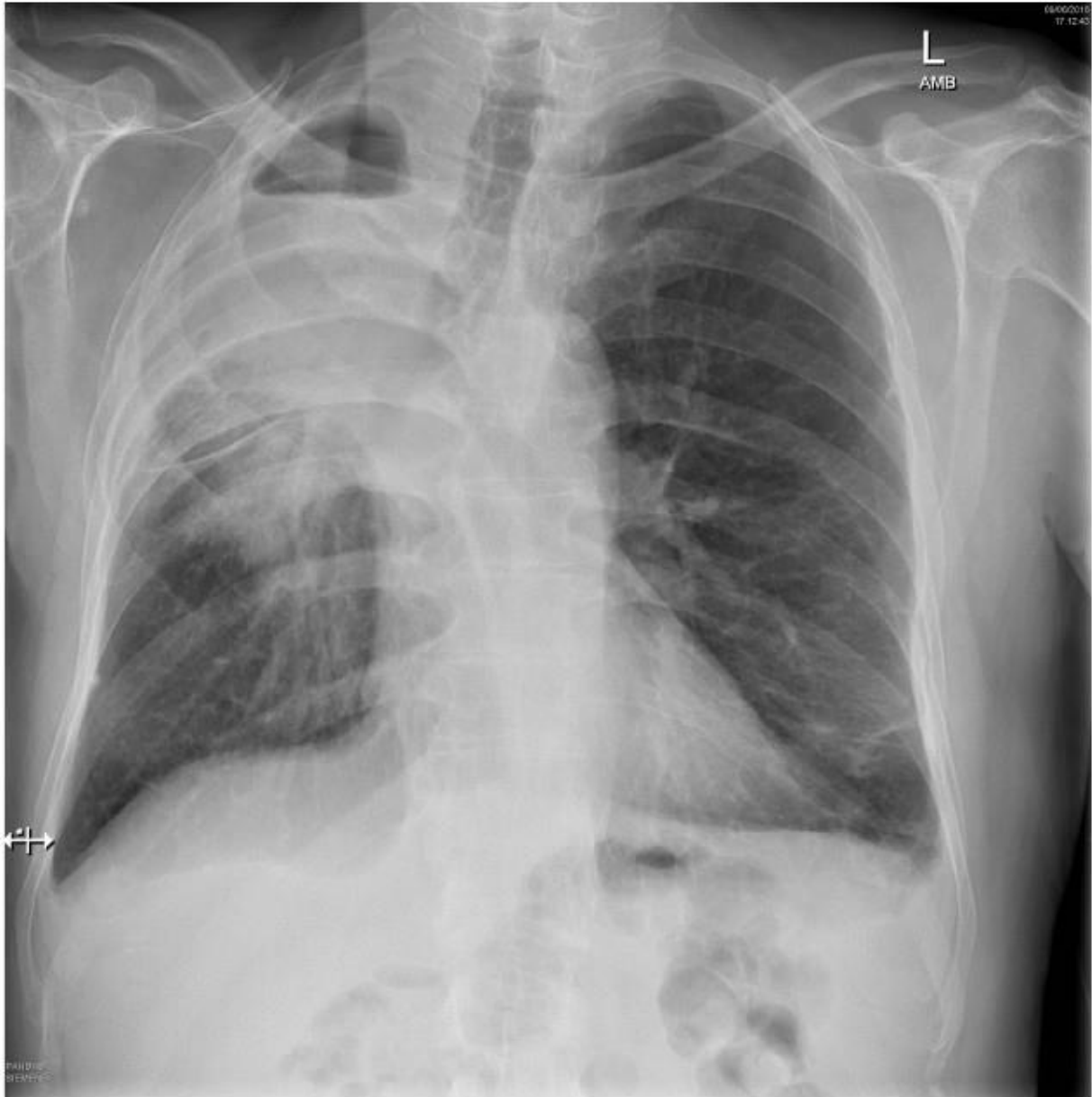


Candidate initials: \_\_\_\_\_

Q12

A 64 year old man has been referred to ED with dyspnoea.

His CXR is shown below.

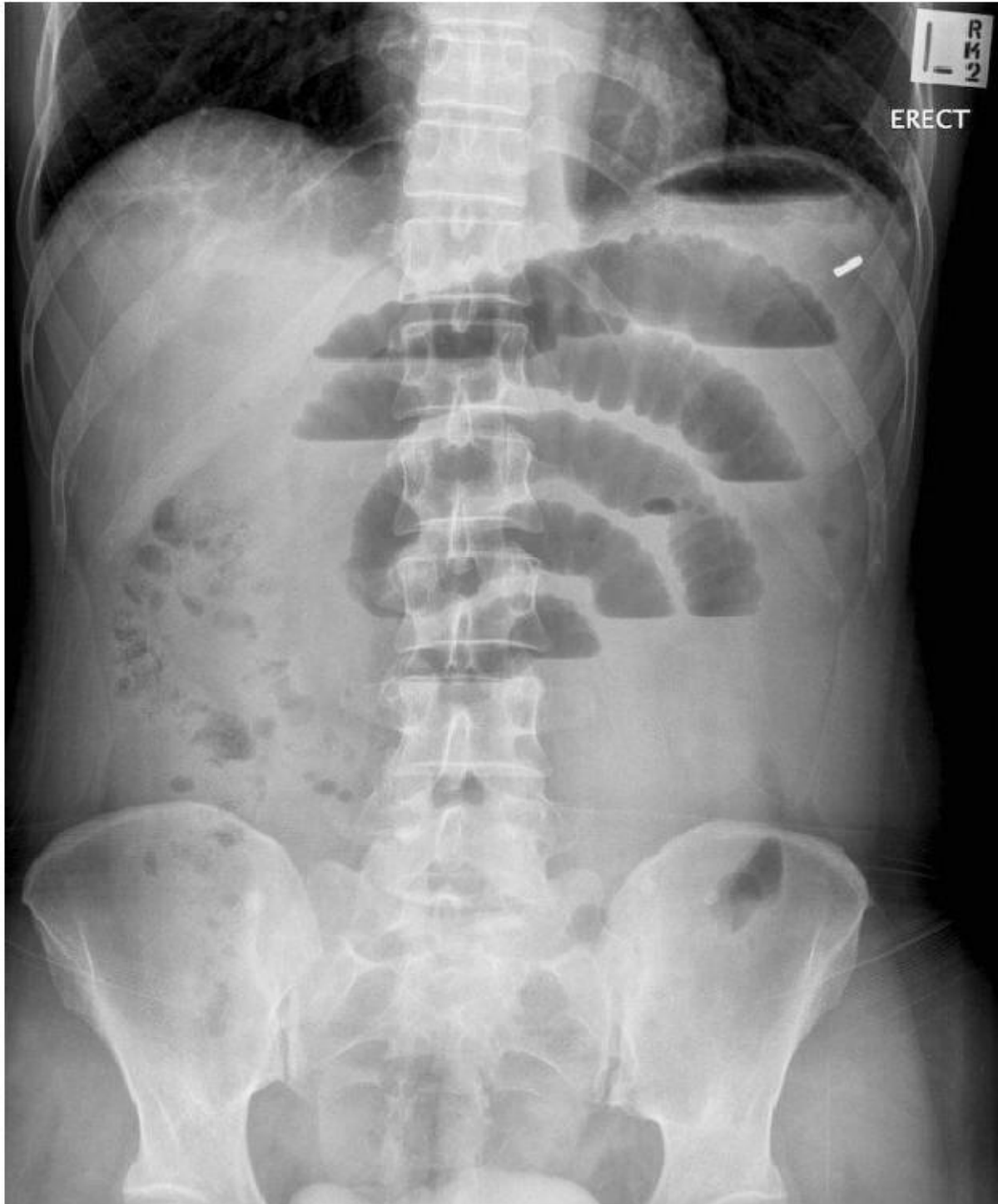


Candidate initials: \_\_\_\_\_

Q13

A 45 year old man has been brought to the ED with abdominal pain for 6 hours.

His abdominal x-ray is given below.

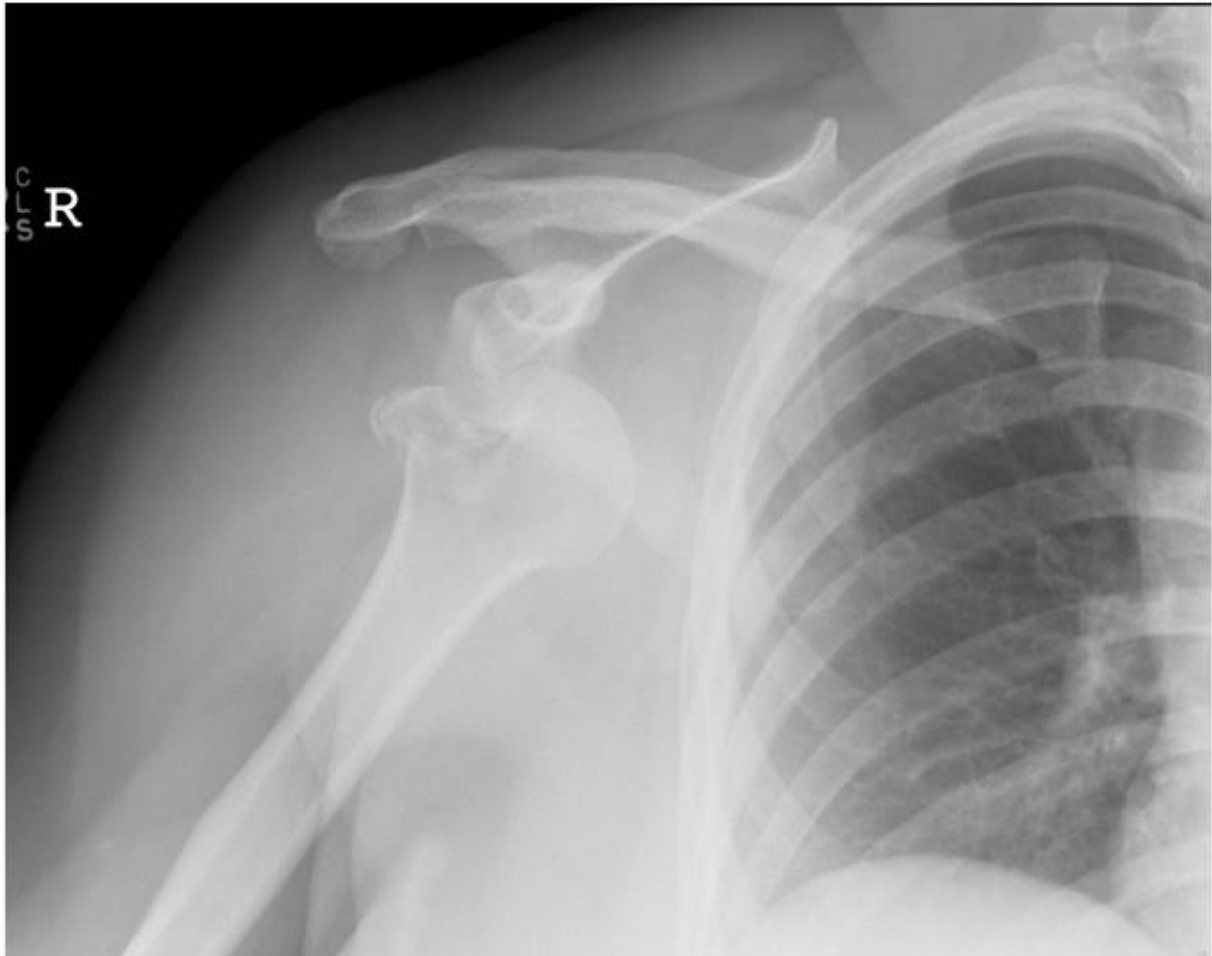

Candidate initials: \_\_\_\_\_

Q17

A 45 year old man has presented to the ED with right shoulder pain after falling on to his right arm while playing basketball.

His right shoulder x-ray is given below.





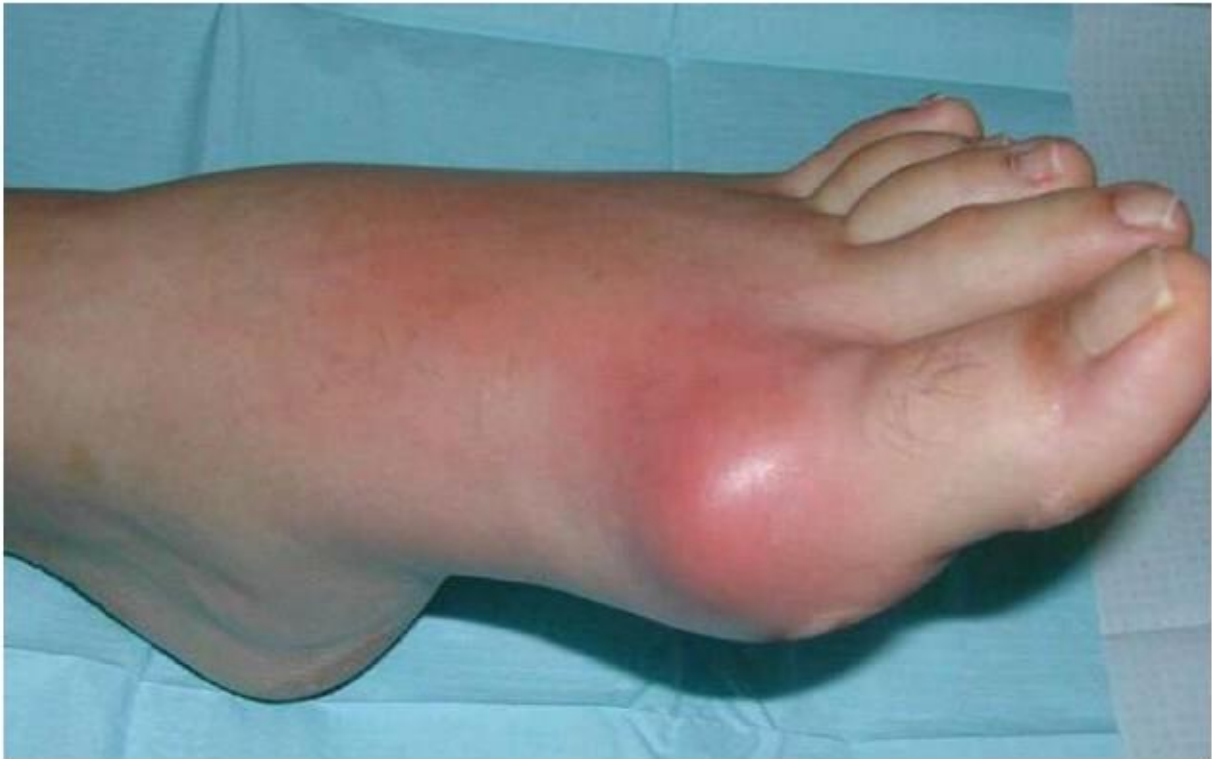Candidate initials: \_\_\_\_\_

Q18

A 58 year old woman has presented with a painful, swollen left foot.

There is no history of trauma nor any previous similar episodes.

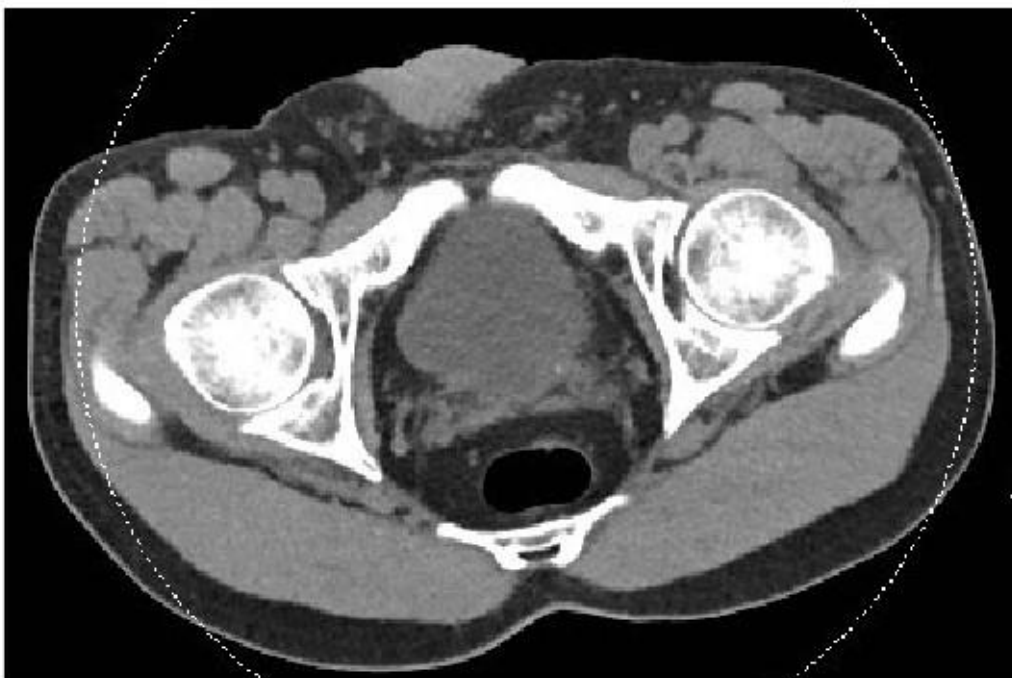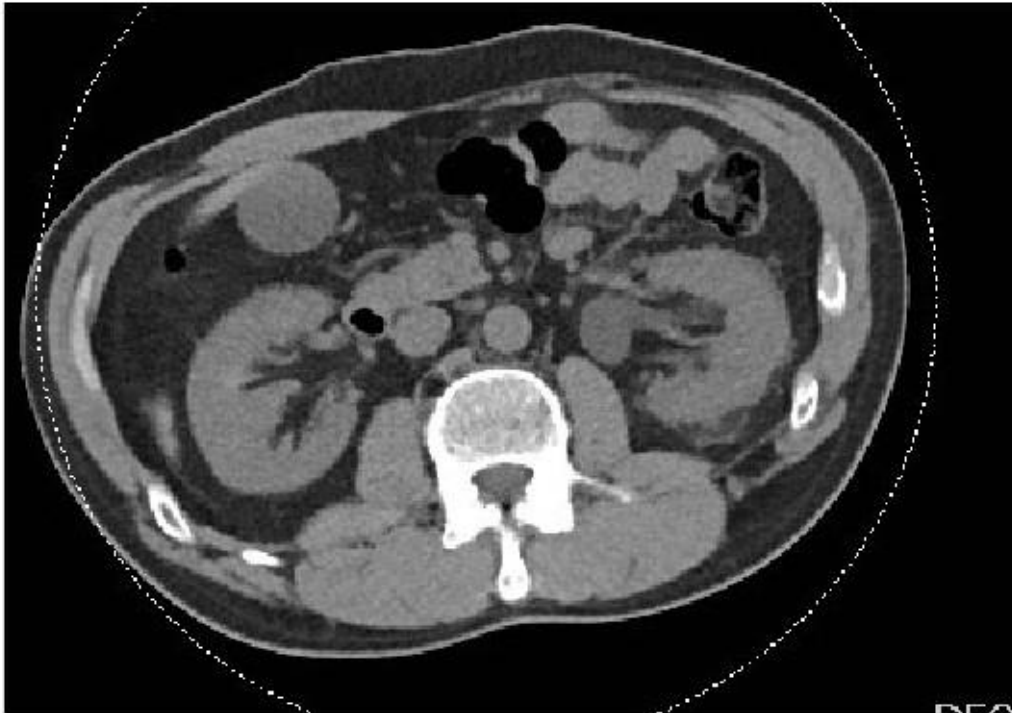A photograph of her foot is given below.



Q22

A 45 year old man has presented to the ED with left sided abdominal pain.

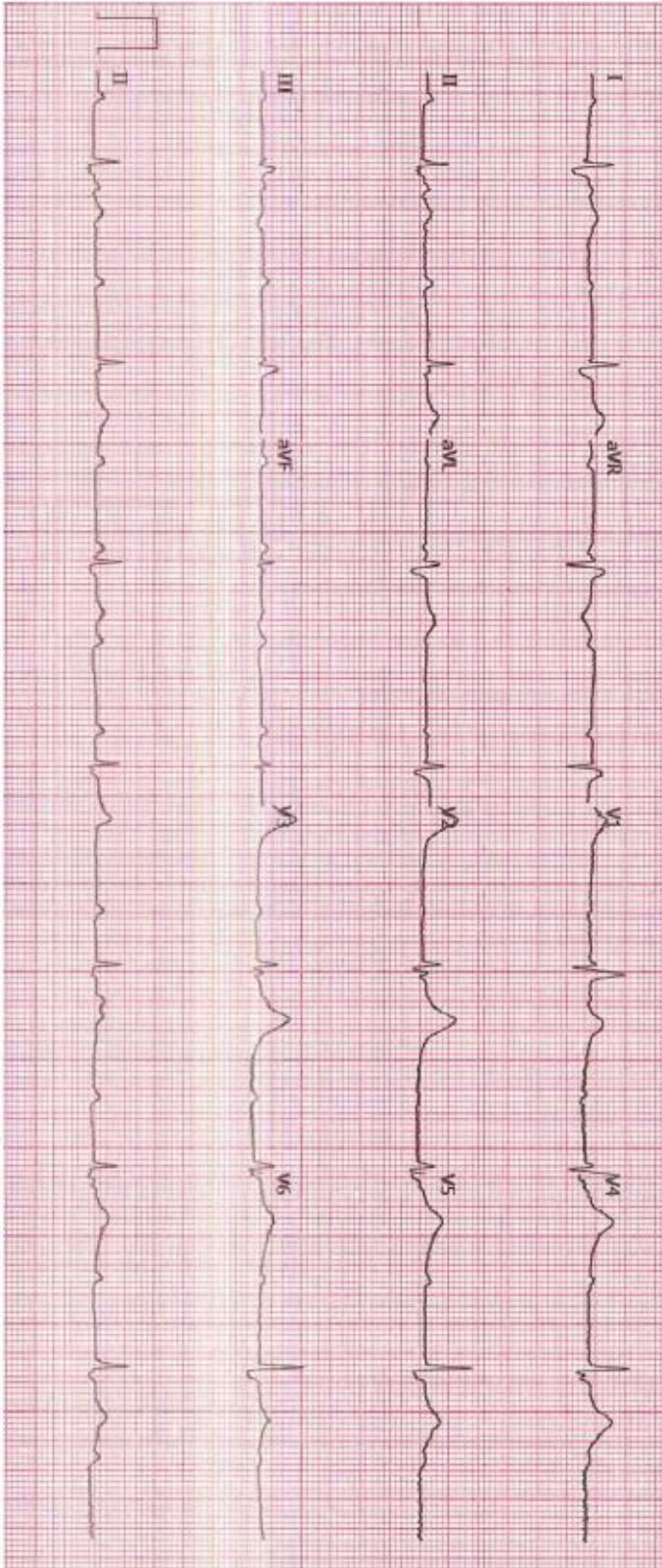
Two images from his abdominal CT scan are provided below.



Q23

A 70 year old man has presented to the ED with dizziness.

His ECG is given below.

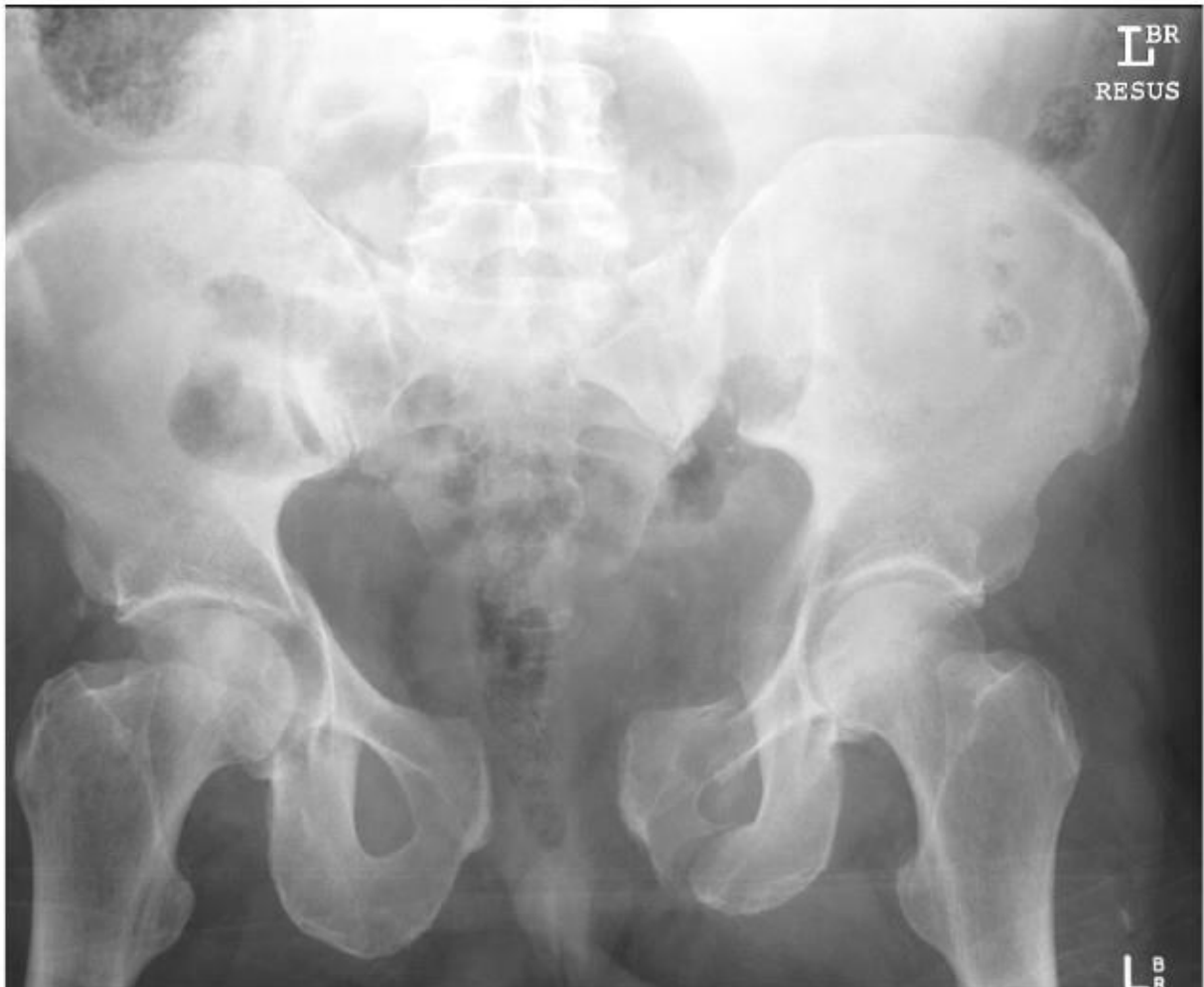

Candidate initials: \_\_\_\_\_

Q25

A 45 year old man has been brought to the ED after falling off a horse.

His pelvic x-ray is shown below.



Q27

A 30 year old male has presented after an intentional slow-release paracetamol overdose.

After initial assessment, the patient was commenced on an N-AcetylCysteine infusion whilst awaiting results. Their serum paracetamol at 6 hours is shown on the nomogram below.

