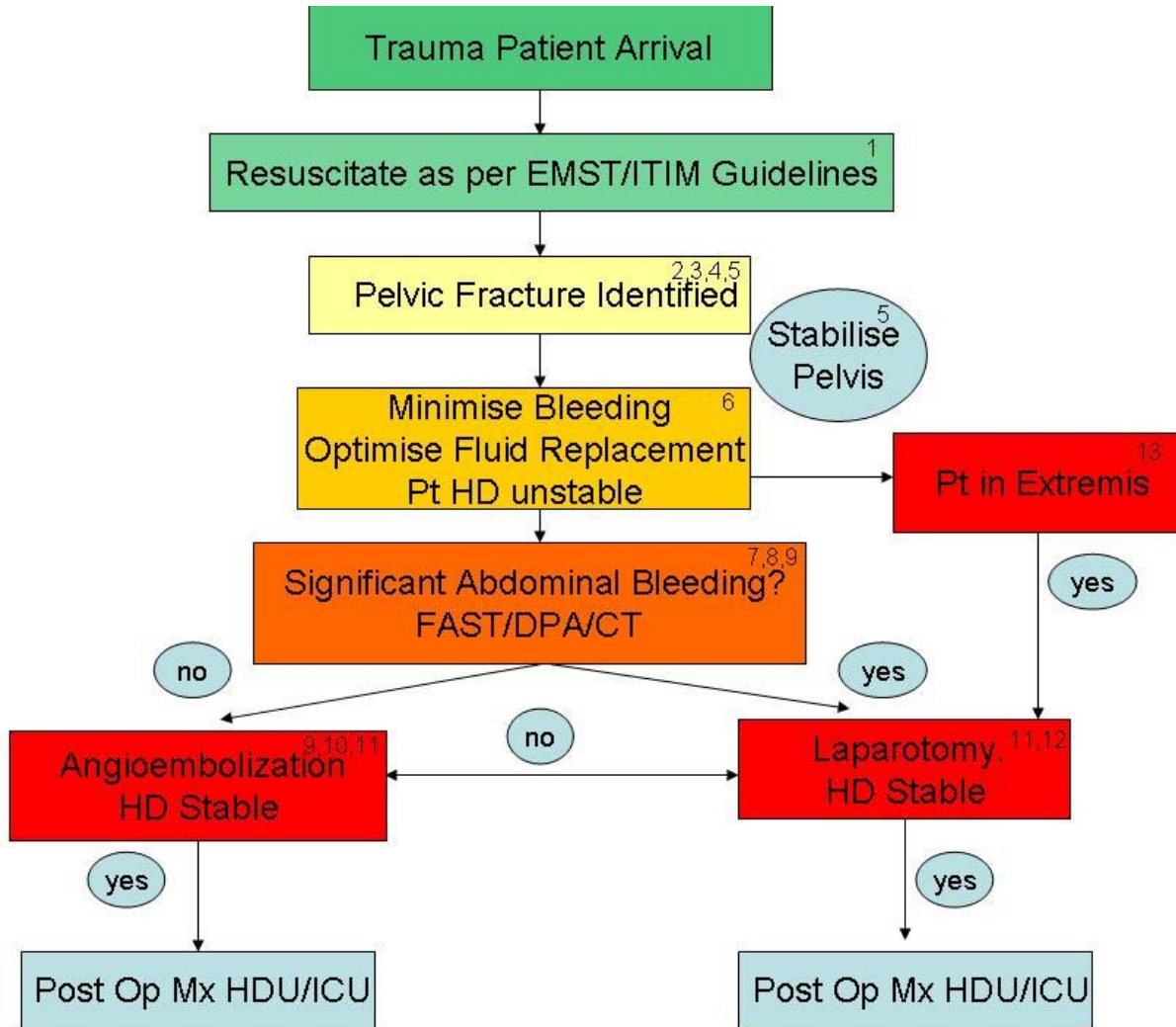


Guidelines For The Management Of Haemodynamically Unstable Patients With Pelvic Fractures

The relative contribution of the various injuries to blood loss, and the appropriate order and method by which they should be investigated and treated, are often unclear. The unstable patient with a pelvic # represents one of the commonest and most difficult patients as both the intra peritoneal and retroperitoneal spaces are unreliable to clinical assessment and accommodate large volume blood loss.

The suggested pathway for management of these patients is presented below, with accompanying clarification of points 1 – 12.



1. Ensure threatened airway and/or thoracic injuries are attended to as per the primary survey. Stop obvious external bleeding, reduce long bone fractures. Search for 'occult' blood loss in the thoracic, abdominal and pelvic cavities.
2. Pelvic fracture should be confirmed by Pelvic Xray or CT scan.
3. A major pelvic # is one which occurs at or posterior to the acetabulae, and is considered to be at risk of significant haemorrhage. Fracture site and venous bleeds are far more common than arterial bleeding.
4. Mechanically unstable #s clinically separate with AP and/or lateral compression and/or vertical stressing, or may be radiologically unstable – defined as >1cm displacement in #s posterior to the acetabulae or >2cm diastasis of the pubic symphysis or other structures anterior to acetabulum. Open book and vertical distraction fractures are more likely to have arterial bleeding.

5. Diagnosis should be suspected with significant mechanism of injury, complaints of pelvic pain or tenderness, visible pelvic bruising or deformity, or pelvic haematoma on FAST scan. Clinical pelvic stressing **should not** be performed if suspicion of injury is high, rather the pelvis should be stabilised utilising bed sheet or belt with any suspicion of pelvic fracture, even before radiological confirmation. Such measures have been shown to be effective in reducing blood loss, and preserving haemostatic clot but radiological confirmation of fracture reduction must be sought, and repetitive pelvic stressing, including repeated log rolls, hip abduction avoided. Urethral catheterisation may follow binding once contraindications have been excluded. **Do not** perform a urethrogram or cystogram until angioembolization has occurred, or the possibility of angioembolization need excluded.
6. If a major pelvic fracture is strongly suspected or confirmed, warmed fluid and blood product resuscitation should occur, incorporating the 'Massive Transfusion Protocol', and targeting a BP of 80-90 systolic (> 90 systolic if associated head injury) in the first 30 minutes, whilst other bleeding sites are excluded and expertise to arrest bleeding are sought. Beyond 30 minutes, resuscitation should be guided by usual endpoints of end organ perfusion. A patient is considered haemodynamically unstable if he has received > 2000 mls fluid and has ongoing fluid/blood product requirements, evidence of poor perfusion and suspicion of ongoing bleeding.
7. FAST performed by an appropriately trained person is very specific - if positive for significant free fluid this should indicate the need for emergent laparotomy.
8. DPA is very sensitive, but must be performed early, supra umbilically and by the open technique. Only a +ve aspirate for > 5mls blood indicates the need for emergent laparotomy. Analysis of lavage fluid for RBC > 100 000 may be false +ve in 20% of patients when pelvic #s are present.
9. CT scanning is generally reserved for the **haemodynamically stable** patient. It should be recognised, however, that where there is an anticipated delay in the arrival of Surgical expertise, it may be prudent to perform a CT scan, provided the Emergency Team Leader and Surgical Consultant are in agreement that this occur.
10. If a CT Abdominal scan has not already been performed, this is usually indicated prior to angioembolization, to aid decisions on likelihood and efficiency of successful arterial bleeding cessation, but the decision is at the discretion of the Interventional Radiologist. In this case CT Abdominal scan should immediately precede angioembolization.
11. Embolization is very effective (90 – 100%) for the cessation of pelvic arterial bleeding in the setting of pelvic #s, but must be considered early, ideally within 45 minutes (<3hrs, < 6 units PC for optimal outcome). It may be performed in the angio suite or the OT. If CT unexpectedly shows a significant intra-abdominal bleed or the patient has evidence of post embolization abdominal bleeding a laparotomy may be indicated.
12. If laparotomy is indicated, continued pelvic fixation before the initial incision limits pelvic movement and further retroperitoneal blood loss.
13. **Pelvic packing at laparotomy may be considered, or may be the initial choice, in the profoundly shocked patient to unwell to go to CT or angioembolization.**

Drafted by:

Dr Donovan Dwyer, April 2002

Input and Approval by:

Trauma Committee (implemented January 2003)

Revised by:

Dr Donovan Dwyer May 2008